

Shape and location of torus palatinus and torus mandibularis among patients attending dental clinic

Ghayda`a H. AL-Izzi B.D.S., M.Sc.⁽¹⁾

ABSTRACT

Background: The aim of this study was to determine the shape and location of torus palatinus (TP) and torus mandibularis (TM) among a group of edentulous patients.

Materials and methods: Out of 720 edentulous patients fifty three subjects were found to have tori at College of Dentistry / Baghdad University. Clinical examination was applied to assess the presence of tori, also a final cast for each patient was made for reassurance of the presence of these tori.

Results: Tori were found to be more in females compared to males, with no statistically significant differences. Also no significant difference in the percentage of occurrence of tori was recorded between different age groups. The non lobulated Tori appeared more than lobulated. Torus palatinus occurred more than Torus mandibularis.

Conclusion: There are differences in percentage of occurrence of tori with age and gender and in shape and location.

Keywords: Torus palatinus, torus mandibularis. (J Bagh Coll Dentistry 2006; 18(3)9-11)

INTRODUCTION

The most remarkable exostoses of the human jaws are torus palatinus (TP) and torus mandibularis (TM)⁽¹⁾. Torus in general is a smooth rounded anatomical protuberance⁽²⁾. This bony hyperostosis, is common in both the maxilla and mandible⁽³⁾.

Torus palatinus (TP) is sessile nodule of bone and it is a benign osseous growth, found at the midline of hard palate at the junction of the palatine process of maxillary bones^(1,3), and it is not found in all patients. Torus palatinus (TP) varies in size from that of a small pea to a huge enlargement that may even full the palate to the level of occlusal plane⁽⁴⁾. Small tori that do not act as fulcrum point under a denture may not require removal, however even when the torus is small it may act as a fulcrum under a denture if the mucosal covering of the crest and slopes of the ridge and displaceable to a greater extent than the mucosal covering of the torus. In these instances the denture base over the area must be relieved to compensate for the difference on the torus, other wise it should be surgically removed⁽³⁾.

Generally the tori are covered with a thin layer of soft tissue and consequently they are very hard⁽⁴⁾. The covering mucosa varies in quality and quantity and the torus may be smooth or pedunculated⁽³⁾. Torus mandibularis (TM) is a bony protuberance located on the lingual cortical aspect of the mandible.

Commonly it may be seen at the canine and premolar areas^(1,5), mid way between the soft tissues of the floor of the mouth and the crest of the alveolar process⁽⁶⁾.

Although tori are not pathologically significant, they may obscure radiographic details of maxillary sinuses and mandibular premolar⁽¹⁾. These tori vary in size and shape, their mucosal covering is usually thin. Most mandibular tori should be removed before denture construction because relief in the denture base rarely provides comforted. As a rule the patient will not tolerate the denture well with the presence of the mandibular tori⁽³⁾.

The percentage of tori varies widely in different populations ranging from 0.4%-66.5% for torus palatinus (TP)⁽¹⁰⁾ and 0.5%-63.4% for torus mandibularis (TM)⁽¹⁰⁻¹²⁾.

The etiology of tori has been investigated, however no consensus has been found. The postulated causes include genetic factors^(1,4), environmental factors^(1,11), masticatory hyper function and continuous growth^(11,12,14). Recently, the etiology of tori has been postulated to be interplay of multi factorial genetic and environmental factors^(5,11).

Racial differences appear significant with a high prevalence in Asia and Eskimo populations^(10,12). The differences in percentage of tori between genders have also had been reported. Most authors reported torus palatinus (TP) was more frequent in females^(1,11,13).

The present study was performed to determine the shape and location of the tori and to investigate the gender and age related changes of torus palatinus (TP) and torus mandibularis (TM).

(1) Assistant lecturer, Department of Prosthodontics, College of Dentistry, University of Baghdad.

MATERIALS AND METHODS

The samples consisted of 53 Iraqi patients selected from 720 dental patients attended the fourth class Prosthodontics Clinic of College of Dentistry, University of Baghdad. The subjects were divided into three age groups: 35-44, 45-54, 55-65 years.

Data collection divided into 2 days in a week; in every day 90 patients were examined. The presence of tori was assessed by clinical inspection and palpation⁽¹²⁾, questionable tori was recorded as not present⁽¹²⁾. In cases of positive finding, diagnosis was confirmed by examination of final cast of each patient. Recording of torus was done according to their shape (lobulated or not lobulated) and according to their location in maxillary, mandibular or in both jaws.

The statistical package for social science was used for the analysis of the data, to find the distribution of the samples according to age and gender and shape (lobulated or not lobulated). The Chi- square test was applied at significance level of 5 % to test differences between lobulated and not lobulated tori, in male and female subjects.

RESULTS

The distribution of the samples according to the occurrence of the tori by age group and gender is shown in Table 1. Although statistically not significant, tori occurred in a higher percentage in females compared to males ($P>0.05$). Age differences were also statistically not significant.

Figure 1 illustrates the distribution of tori in mandible and maxilla by age and gender. The percentage of occurrence was found to be greater in maxilla compare to the mandible; this was true for both males and females.

The distribution of tori, whether lobulated or not lobulated according to gender and age groups is shown in Table 2. In both genders the not lobulated tori appear to be more than lobulated, this was statistically significant in males but not significant in females as shown in Table 3.

DISCUSSION

The presence of tori and other bony exostoses must be detected and an evaluation of their presence in relation to frame work design must be made⁽⁷⁾, although modification of denture design can at times accommodate for exostoses more frequently. This results in additional stressed to the supporting elements and compromised functions⁽⁸⁾.

The removal of exostoses and tori is not a complex procedure, and the advantages to be realized from such removal are great in contrast to the deleterious effects their continued presence can create. Ordinarily the mucosa covering bony protuberances is extremely thin and friable partial denture components in proximity to this type of tissue may cause irritation and chronic ulceration. Also exostoses approximating gingival margins may complicate the maintenance of periodontal health and lead to the eventual loss of strategic abutment teeth⁽⁹⁾.

Study results agree with the most previous studies as in Asian population and others^(1, 12, 13) which shows the torus palatinus (TP) is more common in females^{1,11,13)}, while torus mandibularis (TM) is more common in males^(1, 10-12).

Lobular torus palatinus (TP) is lesser frequently observed than not lobulated and this is agreed with some authors who reported that the lobular torus palatinus (TP) to be rarest type⁽¹⁾.

The non-lobulated Torus mandibularis (TM) was found to be more than lobulated tori and this is in agreement with the other that reported the not lobulated tori as the most common type^(5,11).

The distribution of both tori as well as the differences with age and gender support the hypothesis that torus should be considered a dynamic phenomenon, responding during life to enviromental and functional factors acting in a complicated enter play with the genetic factors⁽¹¹⁾.

Table 1: Distribution of the sample according to age and gender

Age group Year	Males		Females		Total
	No.	%	No.	%	
35-44	11	55	23	69.70	34
45-54	4	20	8	24.24	12
55-65	5	25	2	6.06	7
Total	20	100	33	100	53

Table 2: Distribution of torus according to age, gender and shape

Age group Year	Male				Female			
	Lobulated	%	Not Lobulated	%	Lobulated	%	Not Lobulated	%
35-44	11	84.62	6	35.294	12	75	21	72.41
45-54	1	7.692	6	35.294	4	25	5	17.24
55-65	1	7.692	5	29.412	0	0	3	10.34
Total	13	100	17	100	16	100	29	100

Table 3: Chi-square values between not lobulated and lobulated tori in (male and female)

Types of tori	Gender	Chi-square	P-value	Sig
Not lobulated lobulated	Male	7.305	0.049	S*
Not lobulated lobulated	Female	1.975	0.578	NS**

*P<0.05 Significant, **P>0.05 Non significant

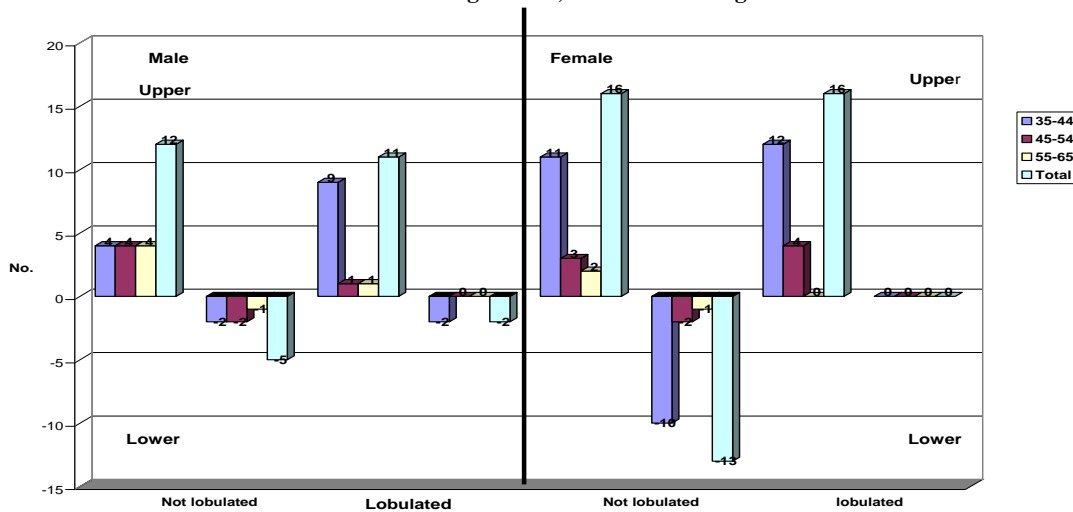


Figure 1: Distribution of toris according to shapes and location in males and females (maxillary and mandibular)

REFERENCES

1. Apinhasmit W, Jainkillivong A, Swadison S. Torus palatinus and torus mandibularis in a Thai population. Science Asia 2002; 28: 105-11.
2. The Glossary of prosthodontic terms. J Prosthetic Dent 7th ed. 1999; 81:103.
3. Rahn AO, Heartwell CM Jr. Text book of complete Dentures. 1993; p. 176-7.
4. Hickey JC, Zarb GA, Bolender CL. Boucher's prosthodontic treatment for edentulous patients 9th ed. St. Louis: CV Mosby; 1985; p. 86.
5. Neville BW, Damm DD, Allen CM, Bouquot JE. Oral and maxillo facial pathology 1995; p. 17-20.
6. Hickey JC, Zarb GA, Bolender CL. Boucher's prosthodontic treatment for edentulous patients 9th ed. St. Louis: CV Mosby ; 1985; p. 183-5.
7. Henderson D, McGivney GP, Castleberry DJ. McCracken's . Removable partial prosthodontics; 9th ed. 1994; p. 216.
8. Henderson D, McGivney GP, Castleberry DJ McCracken's. Removable partial prosthodontics. 7th ed . 1985; p. 238-9.
9. Henderson D, McGivney GP, Castleberry DJ McCracken's. Removable partial prosthodontics. 9th ed. 1994; p 262-3 .
10. Austin JE, Radford GH and Banks SO JR. Palatal and mandibular tori in the Negro . NY State Dent J 1965; 31: 187-91.
11. Haugen LK. Palatine and mandibular tori. A morphologic studying the current Norwegian population. Acta Odontol Scand 1992; 50: 65-77.
12. Kerdpon D, Sirirungrojying S. A clinical study of oral tori in southern Thailand: Prevalence and the relation to parafunctional activity. Eur J Oral Sci 1999; 107: 9- 13.
13. Yasmen TMA, AL-Alousi. Mophometric study of maxillary edentulous arch in Iraqi population sample MSc. Thesis, College of Dentistry, Baghdad University. 1992;. p. 90.
14. Topazian DS, Mullen FR. Continued growth of a torus palatinus. J Oral Surg 1977; 35: 845-6.