



Histological structure of the cervical segment oesophagus in goats and sheep (Comparison study)

Ayad Hameed Ebraheem , Bader Khatlan Hameed , Feras Abass Hussein

Department of Anatomy and Histology , College of Veterinary Medicine , Tikrit University , Tikrit , Iraq

DOI: <http://dx.doi.org/10.25130/tjps.23.2018.009>

ARTICLE INFO.

Article history:

-Received: 4 / 10 / 2017

-Accepted: 15 / 11 / 2017

-Available online: / / 2018

Keywords: histology of esophagus in sheep & goat, anterior portion of esophagus in sheep and goat

Corresponding Author:

Name:

Ayad Hameed Ebraheem

E-mail:

Drayadibrahim@gmail

Tel:

Affiliation

Abstract

Twelve adult animals of both goats and sheep were used in this study. The segments of oesophagus from the anterior 3rd (cervical part) were taken from six samples of goats and six samples of sheep. The segments of 0.5cm were processed by histological techniques which were stained by haematoxylin and eosin and examined under light microscope. The results of this examination revealed that, both species of animals had the for layers which were the tunica mucosa, submucosa, muscularis and adventitia, the mucosa had stratified squamous epithelium with variable amount of keratin on its surface, the lamina propria was formed by dense connective tissue with the presence of thin zone of muscularis mucosa, while in sheep the keratin on the surface of epithelium was more and the lamina propria was thinner than goat, but the muscularis mucosa was formed by masses of smooth muscle fibers more than goat. The sub mucosa was more condensed with connective tissue in goat than sheep with the presence of medium and small sized blood vessels. In this layer in both animals. The tunica muscularis of both were formed by skeletal muscle fibers, in goat were arranged into three directions which were inner circular, middle oblique and outer longitudinal, while in sheep was found as inner circular and outer longitudinal. finally, both animals were containing outer layer of loose connective tissue called tunica adventitia and in sheep had more fat cells invaded this layer with blood vessels, fat cells and nerves.

Introduction

The oesophagus of the goat was studied by [1], they demonstrated that the innervation of the oesophagus is an important in anatomical research as it is an important organ of digestive system, having several complications, like faulty drug administration through stomach tube, choke, oesophagitis, tracheo-oesophageal fistula and esophageal stricture .

Oesophagus is a tube like passage from the mouth to the stomach [2]. The oesophagus is open into the stomach at the junction with the reticulum and rumen, which helps to transport both gases and cud[3]. The oesophagus is divided into two segments which are cervical and thoracic [1].

The epithelium has been reported, slightly keratinized especially in the caudal region [4].

There is no information available for the comparison of anterior part in both sheep and goat,

so this study was designed to explore the histological architecture of the oesophagus in the above species.

Materials and Methods

Twelve oesophagus was obtained from the six sheep, and six goats, the age was more than twelve month for each, the whole specimens were collected from the abattoir of Baghdad. Segments of 0.5cm from anterior portion of the each oesophagus was taken and immersed in 10% formalin for 24 hours followed by immersion in graded series of alcohol from 70% until 100%, then clearing with xylene and embedded in paraffin wax at 68°C. Blocking of the samples were made and the sectioning were performed using a rotary microtome. The thickness of the sections were 6 micrometres. The tissue section after application of staining with Haematoxylin and Eosin were mounted on the slides using D.P.X and covered by cover slides [5].

The slides were examined using light microscope and photographed by manipulated camera prepared for this purpose.

The results

A- Goats

The epithelium of the goat was stratified squamous resting on the undulating basement membrane which intermingled with the underlying lamina propria (Fig. 1) forming a papillae (finger like), the basal layer of the epithelium was containing many granules in the cytoplasm and its nuclei was also contained lots of chromatin granules. The stratum spinosum was present toward the surface of the lumen had scale like cells with large nuclei and the cytoplasm was whitish color, the outer most layer was flattened and some of its cytoplasm were desquamated and its nuclei were pyknotic. The outermost surface was covered by a thin layer of keratin (Fig. 2).

The lamina propria was formed by collagen bundles and elastic fibers, these are packed together , and were associated with the presence of blood vessels of small sized and capillaries, also the nervous plexus were noted in this layer.

The submucosa was formed by loose connective tissue associated with the presence of medium sized blood vessels and blood capillaries, also the nervous plexus were also present with the fat cells also shown (Fig. 3).

The deepest layer of the submucosa was associated with the blood vessels. The tunica muscularis was formed by bundles of the skeletal muscle fibers invested by loose CT. These are arranged into three

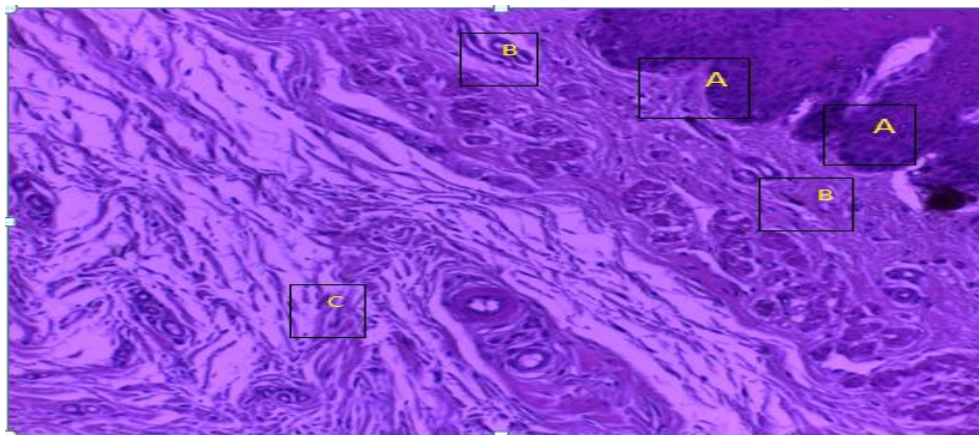
layers, inner circular, middle oblique and outer longitudinal which invested by the loose CT(Fig 4,5).

B- sheep

The epithelium was formed by stratified squamous, Its outer layer was highly folded (Fig. 6), this layer was subdivided into the basal layer which was the stratum basale enriched by a lot of chromatin in its nuclei, with the presence of columnar epithelial cells resting on underlying basement membrane(Fig.7). The stratum spinosum of this layer was formed by many rows of scale like cells, some of these cells were present with whitish color with prominent nuclei, these cells became flattened toward the desquamated surface. The epithelium was overlapped with the beneath lamina propria forming small papillae. The lamina propria was formed by collagen bundles which were packed together with the presence of blood capillaries, this layer was demarcated from the sub mucosa by muscularis mucosa (Fig. 8) is supported with small masses of smooth muscle fibers and the sub mucosa was formed by loose connective tissue associated with the presence of the adipose connective tissue. The blood vessels of medium and small sized also were seen.

The tunica muscularis was formed by bundles of skeletal muscle fibers which were arranged into innermost circular direction (Fig.9) and the outermost which was longitudinal direction which was thinner than the innermost(Fig.10).

The tunica adventitia was formed by loose CT and adipose tissue (Fig.11) with nerve ending and blood vessels which were covered. This layer was thinner than that of the goat and more delicate (Fig.12).



Fig(1):- Stratified squamous epithelium of goat (A). Decrease of connective tissue of lamina propria (B) with minute blood vessels and submucosa (C) (H&E X4)

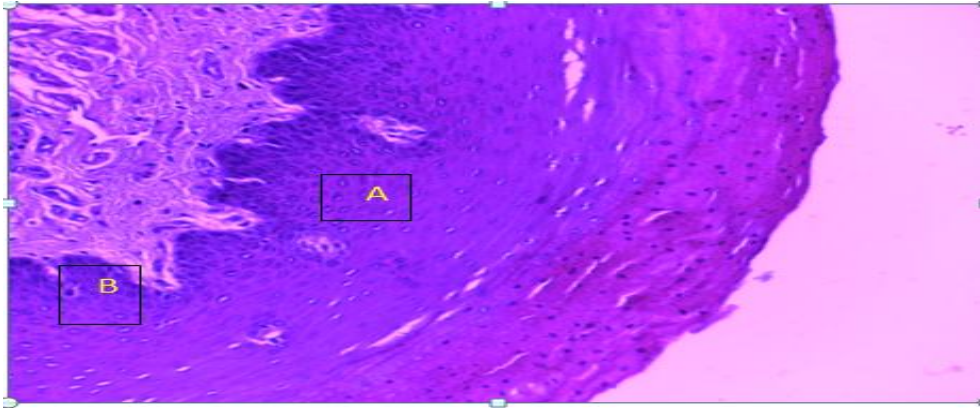


Fig (2):- Stratified squamous epithelium of goat (A), Basal layer with papillae(B) (H&E X10)

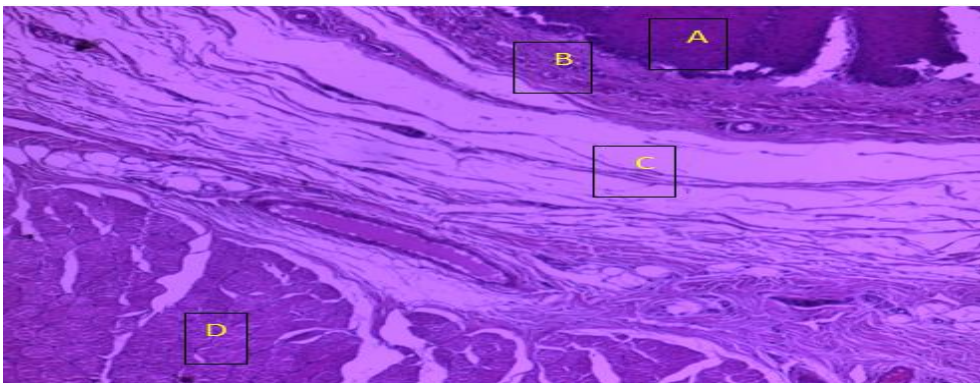


Fig (3):- Stratified squamous epithelium of goat (A), Lamina propria (B), Submucosa (C) and tunica muscularis (D) (H&E X10)

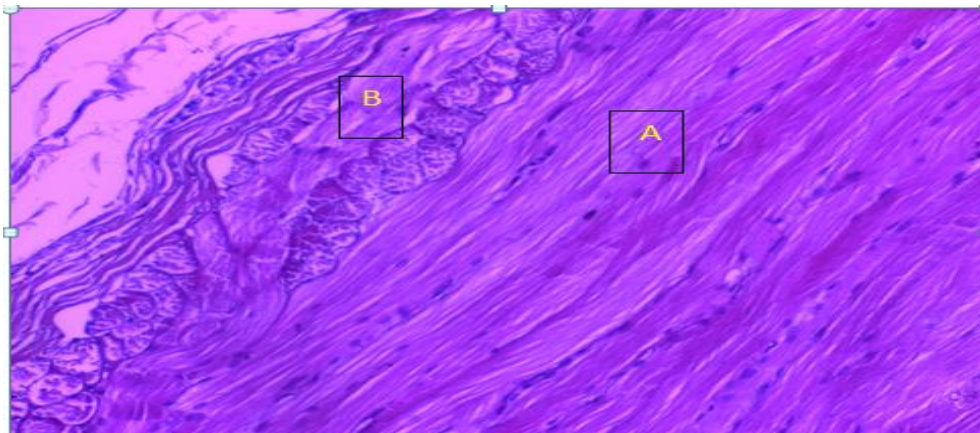


Fig (4):- Skeletal muscle fibers of tunica muscularis of goat , inner circular (A) and outer longitudinal (B) (H&E X200)

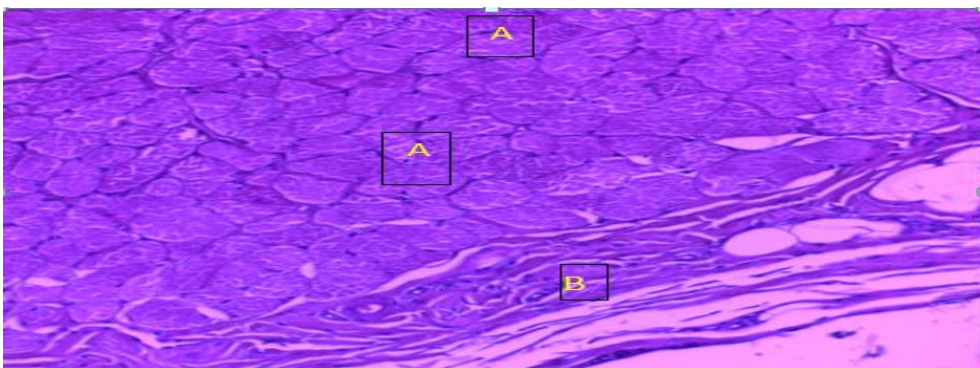
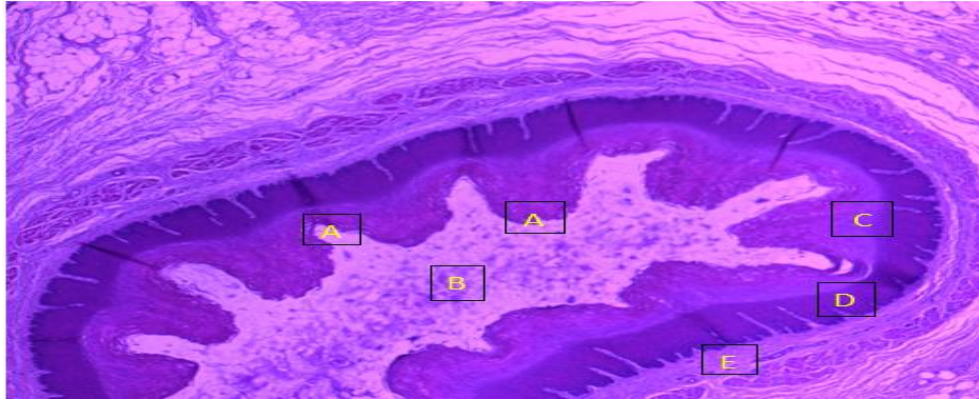


Fig (5):- Outer circular skeletal muscle of goat (A), Tunica adventitia (B) (H&E X10)



Fig(6):- Multiple folds of mucosa of sheep (A), lumen of oesophagus (B), Lamina propria (C) , muscularis mucosa (D) and sub mucosa (E), (H&E X4)

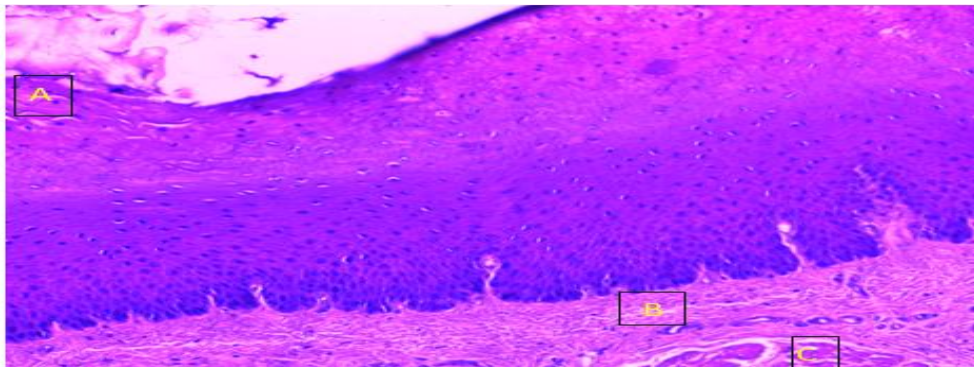


Fig (7):- Stratified squamous epithelium with keratin in sheep (A),dense lamina propria with minute blood vessels (B), muscularis mucosa (C) (H&E X10)

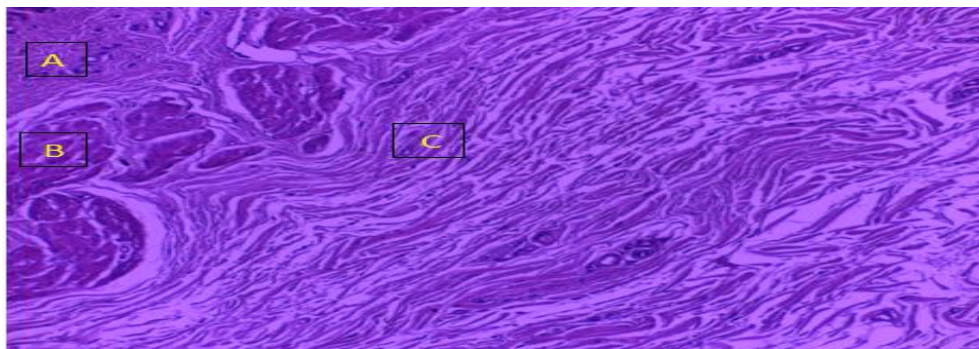


Fig (8):- Lamina propria (A), Muscularis mucosa (B) and dense connective tissue of submucosa in sheep (C) (H&E X4)

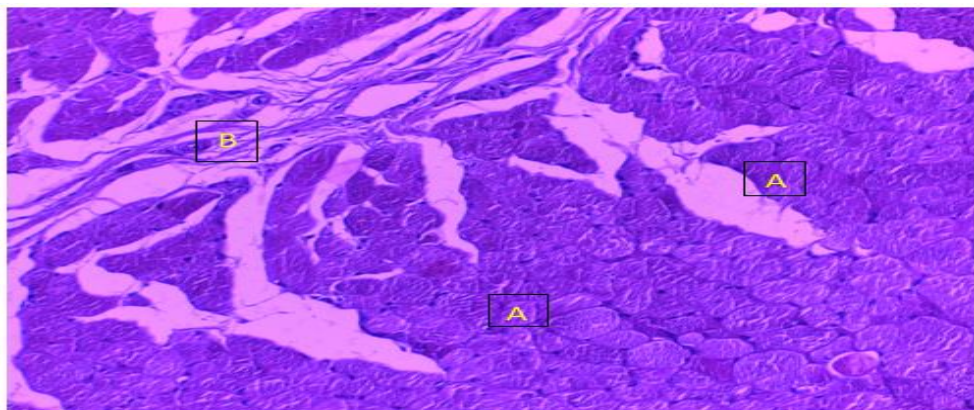


Fig (9):- Extensive layer of skeletal muscle bundles of sheep (A), Connective tissue of Perimysium (B) (H&E X10)

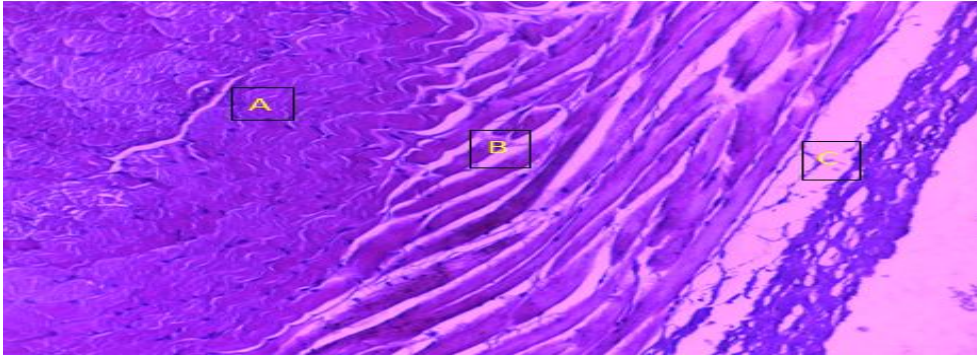


Fig (10):-Inner circular layer of tunica muscularis in sheep (A), outer layer (B) and tunica adventitia (C) (H&E X10)

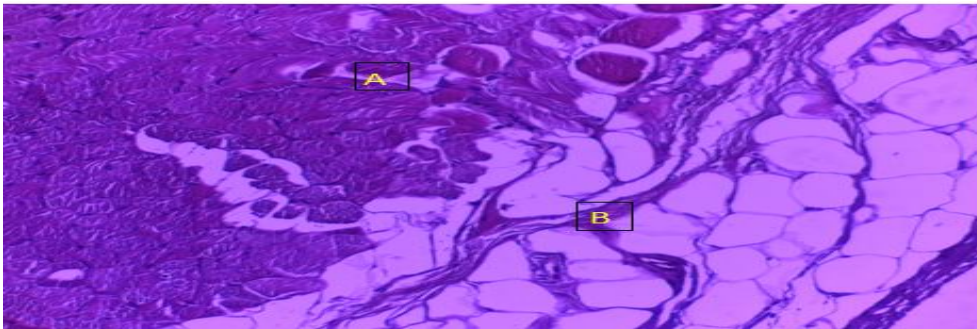


Fig (11):-Tunica muscularis of sheep (A) an outer layer, tunica adventitia with adipose tissue (B) (H&E X10)

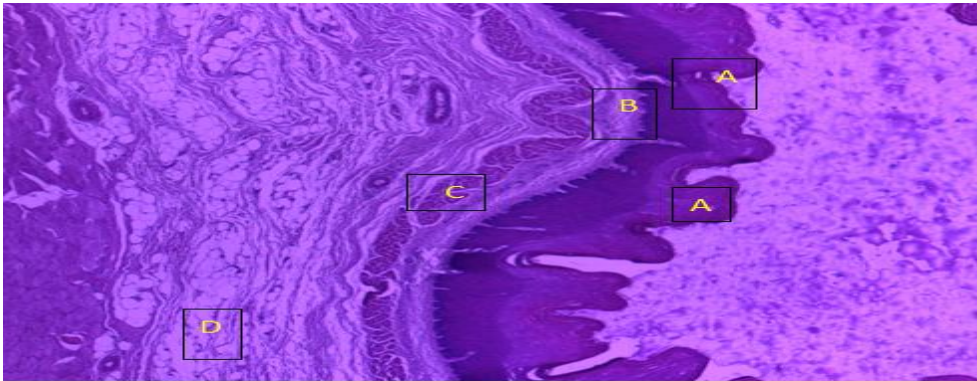


Fig (12):- Stratified squamous epithelium with multiple folds on its surface in sheep (A), narrow lamina propria (B), muscularis mucosa (C) and submucosa (D) (H&E X4).

Discussion

The mucosa of oesophagus in both goats and sheep's were examined which revealed that the variation in between was seen for the structure was obvious in certain places of the anterior portion (Fig. 2,7), these changes were reflected by the presence of keratin covering the stratified squamous epithelium in the sheep lesser than in goat, and this means that goat consume more roughages food and this demand the presence of more keratin on the outer surface of epithelium, the presence of keratin on the surface of epithelium is related with increased abrasion from the roughage in the diet this interpretation is in agreement with the study of [1] in the Bengal goat, [6] in the porcine esophagus .

The lamina propria of the goat was formed by dense connective tissue and this structure was not differ to that of sheep, but this layer was separated from the

deeper layer which was the sub mucosa in the sheep by many bundles of the muscularis mucosa which was devoid in goat and even the submucosa was not variant in both species, while it has no mucus glands and this finding is in agreement with [3] in the sheep and goat and in ruminant by[4]. However submucosal glands were reported in the cervical part of oesophagus of buffalo [7].

There was no variation in the muscular coat of sheep and goat in that, the anterior 3rd was skeletal, extend a long the course of oesophagus as skeletal for both, but the thickness was more in the goat than the sheep, and formed in three directions. This phenomena may reflect the capacity of goat to ingest more food in one bolus and this was noted by [6] in the goat that, the passage of a mass of food in one bolus demand a force effort to push it toward the stomach also this phenomena may reflect the clinical application for the

veterinarian that, the choke in sheep is more than in goat and this was due to increased the force of muscular coat of oesophagus in goat to do peristaltic movement of oesophagus more than sheep, and this lead to push any foreign body toward the rumen faster than sheep [8].

The tunica muscularis in horse is skeletal at the anterior two thirds while the posterior third is smooth[2] and this is differ than that found in goat and sheep of the present study.

References

- 1- Islam, M.S., Awal, M.A., Quasem, M.A., Asad uzzamay, M and Das, K. Morphology of oesophagus of Black Bangal Goat. J. Vet. Med. 6 (2). 2008. 223-225.
- 2- Konig, H.E and Liebich, H.G (2004): Veterinary Anatomy of Domestic Mammals
- 3- Ensimnger, M.E (2002): Sheep and Goat Science. 6th ed. Danville IL. Interstate Publisher Inc.
- 4- Dellman, H.D (1993): textbook of Veterinary Histology . 6th ed. Lea and Febiger. Philadelphia
- 5- Bancroft, J.D and Steven, A (1982): Theory and practice of histological techniques. 2nd ed. Churchill Livingstone. Edinburgh. London. Melbourne and N.Y.

Finally the tunica adventitia at the anterior third of oesophagus of both was formed by loose connective tissue gradually transformed into tunica serosa in the posterior two thirds of the thoracic and abdominal parts, so this result is in agreement with [4, 9,10] of that the loose connective tissue in the anterior one 3rd of esophagus was tunica adventitia and when covered by mesothelial cells of simple squamous epithelium of the posterior two 3rd in the thoracic and abdominal regions become tunica serosa.

- 6- Ann, J and Eurell, C (2004): A textbook of Veterinary Histology.
- 7- Gupta, S.K and Sharma, D.N (1991): Regional Biology of the oesophagus of Buffalo Calves. Ind.J. Anim. Sci. 61. 722-724.
- 8- Banks, W.J (1986); Applied veterinary Histology. 3rd ed. Mosby year book. Baltimore
- 9- Kumar, P., Mahesh, R and kumar, P (2009): Histological Architecture of oesophagus of goat (Capra Hircus). Haryana Vet. J. 29-32.
- 10- Aughey, Elias and Fredric, F (2001); Comparative Veterinary Histology with Clinical correlation. Chapter (8) 97.

التركيب النسيجي للجزء العنقي للمرئ في كل من الماعز والاغنام (دراسة مقارنة)

اياد حميد ابراهيم ، بدر ختلان حميد ، فراس عباس حسين

فرع التشريخ والانسجة ، كلية الطب البيطري ، جامعة تكريت ، تكريت ، العراق

الملخص

تم استخدام اثني عشر حيوان من كل من الماعز والاغنام في هذه الدراسة. اخذت عينات من المرئ للجزء الامامي العنقي لستة عينات من الماعز ومثلها من الاغنام وبحجم نصف سم مكعب. جميع العينات اجريت عليها التقنية النسيجية والصبغ بالهيماتوكسلين والايوسين، ثم الفحص تحت المجهر الضوئي. اظهرت النتائج من هذا الفحص بان كلا الجنسين لها تركيب متشابه في هذا الجزء من المرئ وهو مؤلف من غلالات هي، الغلالة المخاطية، الغلالة تحت المخاطية، الغلالة العضلية والغلالة البرانية. الغلالة المخاطية في الماعز تكونت من ظهارة مطبقة حرشفيه مع تباين في وجود مادة الكيراتين على سطحها، ووجود الصفحة الأساسية المكونة بواسطة نسيج رابط كثيف ووجود عضلة المخاطية كنطاق ضيق من الحزم العضلية الملساء، بينما في الاغنام طبقة الكيراتين على سطح الظهارة كانت اكثر والصفحة الاساسية مؤلفة من طبقة رقيقة من النسيج الرابط مقارنة مع الماعز وعضلة المخاطية كانت اكثر كثافة مما في الماعز. الطبقة تحت المخاطية كانت اكثر كثافة كنسيج رابط في الماعز مما في الاغنام، مع وجود اوعية دموية متوسطة الحجم وصغيرة في كلا الجنسين. الغلالة العضلية في الماعز ترتبت بثلاث اتجاهات داخلي دائري، وسطي مائل وخارجي طولي وجميعها من النوع الهيكلية، بينما في الاغنام كانت مرتبة داخلي دائري وخارجي طولي ومن النوع الهيكلية ايضا. اخيرا فان الغلالة البرانية تألفت من نسيج رابط رخو في كلا الجنسين واحتوت على اوعية دموية واعصاب مع وجود خلايا دهنية في الاغنام اكثر مما في الماعز.