

## Scalp Burns: Evaluation of electrical versus Thermal Scalp Injury

Ahmed A.K.Mohammed Nawres

### ABSTRACT:

#### BACKGROUND:

Scalp burns present as functional and aesthetic problems. The line of management depends mainly on the depth of burn wound and the presence or absence of underlying bone involvement.

#### OBJECTIVE:

We demonstrate the differences between thermal and electrical scalp injuries regarding depth and management.

#### METHODS:

Records of all burned patients admitted to Hilla General Teaching Hospital between April 2004 and June 2006 were reviewed. Ten patients with electrical scalp injuries were identified and compared with twenty patients with thermal scalp burn.

#### RESULTS:

The incidence of calvarial bone involvement was 100 % in electrical scalp injured patients while all patients with thermal scalp burn were partial thickness (bone free) during the study period. The mean age was eighteen years for the electrically injured patients (ranged from 14 to 30 years) and four years for the thermally burned patients (ranged from 2 to 8 years). Treatment was achieved with early bone debridement and immediate local scalp flaps coverage for electrical scalp injured patients while most of thermal scalp burned patients were healed spontaneously.

#### CONCLUSION:

Debridement of the electrically injured scalp with flap coverage is advisable to be performed with in 3<sup>rd</sup> to 5<sup>th</sup> day after the injury rather than waiting for the settlement of the progressive necrosis, the known unique effect of electrical current.

**KEY WORDS:** Scalp, electrical injury, thermal burn.

### INTRODUCTION:

Electrical injuries account for less than 5% of admissions to major burn centers. The mortality is reported to be between 3% and 15%, with about 1000 deaths a year in the United States attributed to electrical injury<sup>(1,2)</sup>. Electrical injury may be low voltage (<1000 volts), high voltage (usually >1000 volts), and lightning strikes (extremely high voltage)<sup>(1, 2)</sup>. Injuries associated with low voltage are most likely to occur at home while those with high voltage typically occur outdoors near power sources. Electrical current can arc (jump) 1 inch from a power source for every 10,000 volts<sup>(2)</sup>. Luce and Gottlieb have divided the high voltage injuries into flash and true types. The former are caused by a flame of very high temperature and short duration due to the conversion of electrical energy to heat outside the

body. These burns are typically mixed full and partial thickness burns, without characteristic entry and exit wounds. True electrical injuries are caused by the passage of an electrical current through the body between entrance and exit points with significant destruction in these areas<sup>(3)</sup>. Physical evidence of an entrance and exit sites is pathognomonic of the passage of a significant amount of electrical current through the body<sup>(2)</sup>. The main pathomechanics of tissue damage in electrical injury are: (1) Current-generated heating with resulting thermal burn (Joule heating) and (2) Direct electric force denaturation of cell membrane proteins and lipids which lead to the creation of large pores (electroporation). These pores may lead to ion leakage, escape of metabolites and pathologic membrane permeability to macromolecules as large as DNA<sup>(4)</sup>. Electrical injuries are more severe than comparable thermal burn because instead of just having skin burns, it follows the paths of least resistance and involves

Lecturer in plastic surgery , College of Medicine.  
Babylon University .

more internal structures (iceberg effect)<sup>(3)</sup>. A unique effect of an electrical current is an apparent progressive loss of viable tissues occurring in the first few days after the injury due to delayed thrombosis of microvasculature<sup>(5,6)</sup>. The effect of the electric current on the body is determined by many factors table no.1). Thermal scalp burns are usually

partial thickness in type with out underlying bone involvement can usually be treated conservatively with minimal indications for surgical intervention. This study was conducted to demonstrate the differences between thermal and electrical scalp injuries regarding depth and management.

**Table 1: Terminology in electrical injuries**<sup>(2,4,5,7,8)</sup>

|   |
|---|
| <p><b>Household current</b> = 110 to 220 volts<br/> <b>High-tension wire</b> = Up to 100,000 volts<br/>                     Electrical injury: <b>low voltage</b> (&lt; 1000 volts), <b>high voltage</b> (usually &gt;1000 volts), and <b>lightning strikes</b> (extremely high voltage).<br/> <b>The effect is determined by:</b> 1.Type of the current: low voltage Alternating current(AC) is more dangerous than direct current (DC) of the same voltage because it produces muscle tetany impeding attempts to escape from the electric source. 2.Voltage and amperage. 3.Course of the current. 4.Duration of contact. 5.Area of contact. 6.Resistance of the tissue. Electrical current produces heat when it meets a resistance to flow.<br/> <b>Joule's law:</b> heat production defined in terms of Joules (J): <math>J = I^2RT</math> where I = amperage, R= resistance and T = contact time.<br/> <b>The order of tissues from least to most resistant is:</b> nerves, vessels, muscles, skin, tendon, fat, and bone.<br/>                     Bone has the highest resistance, acts like a heating element on an electric range which explains deep periosteous tissue damage occurring in the relative absence of surface wounds. It also dissipates heat more slowly than other tissues so it heats the surrounding tissues even after current ceases to flow.</p> |
|---|

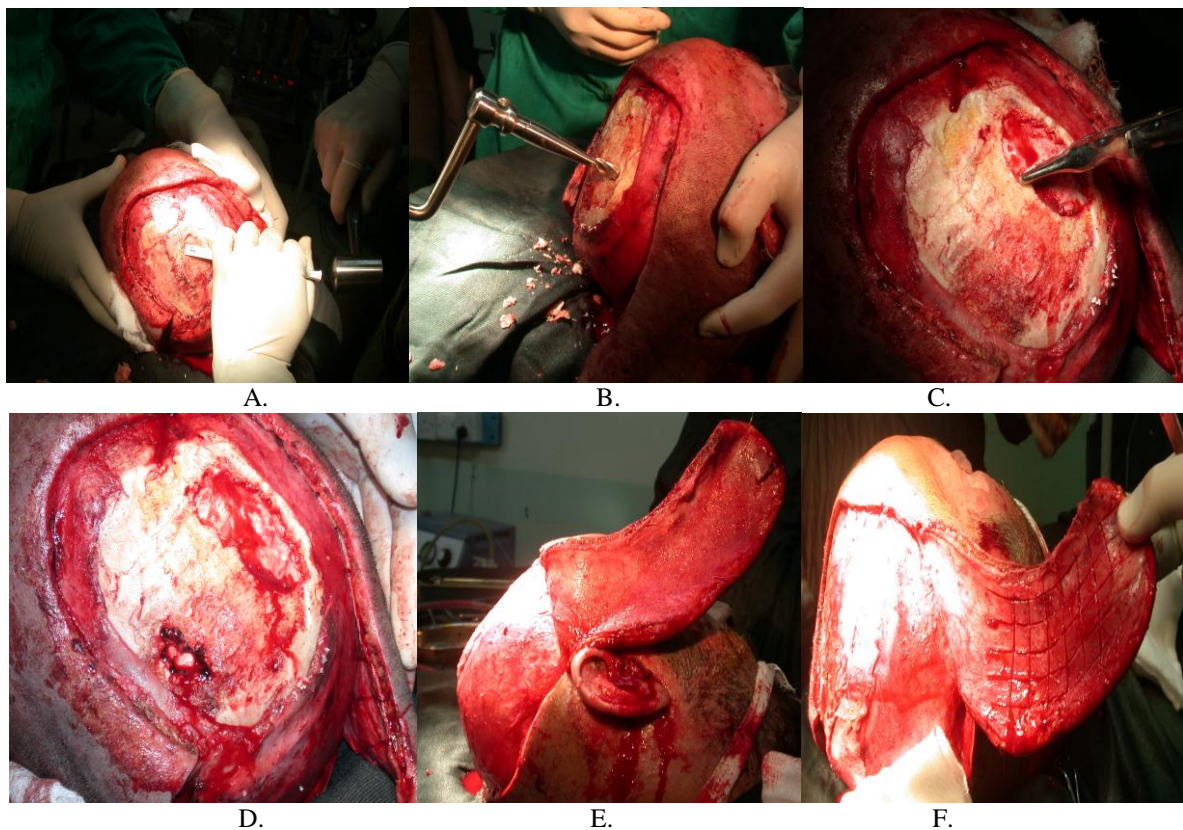
**PATIENTS:**

Records of all burned patients, which include 200 patients, admitted to Hilla General Teaching Hospital in Babylon city between April 2004 and June 2006, were reviewed. Scalp was involved, alone or in combination with other parts of the body, in thirty patients: Ten with electrical injuries (nine males and one female) and twenty with thermal burns (12 males and 8 females). The mean age was eighteen years for the electrically injured patients (ranged from 14 to 30 years) and four years for the thermally burned patients (ranged from 2 to 8 years). Only victims with documented passage of electrical current (with entrance and exit points) were included. All patients with electrical scalp injuries were full thickness with bone involvement (mostly high tension injury affecting the vault) while thermal scalp burned patients, mostly scald, were mainly partial thickness in type (sixteen patients) except four patients with full thickness but with viable pericranium.

**METHODS:**

In patients with electrical scalp injuries, debridements followed by immediate coverage with local scalp flaps were performed within the third to fifth day after the accident. After removal of the involved outer table with the aid of osteotome and bone nibbler (figure 1:A), the inner table was found to

be also affected in two patients, so craniectomy was done, assisted by a neurosurgeon, using Hudson Brace bone drill and bone nibbler (figure 1:B&C). One of those two patients was discovered intraoperatively to have a small extradural hematoma underneath the resected bone which was evacuated adequately (figure 1:D). The resulting circular bone defects in those two patients were 4cm and 10 cm in diameter. Bone wax was used to control the oozing from the resected and decorticated bone. Local scalp flaps (rotational or transpositional flaps) were used for the coverage of scalp defects in all the ten patients (figure 1:E). Scoring the galea with knife was done perpendicular to the direction of desired tissue gain and some time even in reversed directions to obtain more width of the flap (figure 1: F). Skin grafts were used for closure of flap donor sites in eight patients while it was closed directly in two patients (figure 2&3). Patients with thermal scalp burn were mostly partial thickness in type, treated conservatively with twice daily hydrotherapy and local silver sulfadiazine cream application and were healed with in 2 – 3 weeks except four patients with full thickness scalp burn, required split skin graft to cover an intact pericranium.



**Figure 1: Operative views of a young patient with high tension electrical scalp injury. A: Decortication: Removal of inner table with the aid of Hudson Brace drill. C: Bone nibbling: Small extradural hematoma .E: Elevation of local transpositional flap.F: Galea scoring with knife.**

**RESULTS:**

The follow up period ranged from six to eight months, which included postoperative examinations at two days, one week, ten days, one month and 6 – 8 months. All the twenty patients with thermal scalp burn were healed spontaneously with in 2 – 3 weeks except 4 patients with full thickness burn required split skin graft over an intact pericranium (table 2). Nearly all patients with electrical scalp injuries were healed smoothly with in 2 weeks following

early bone debridement and local scalp flap coverage except one patient who developed partial dehiscence of scalp flap with discharging pus from a necrotic small piece of bone for whom an extended craniectomy was performed and the wound closed with the same flap (figure 4). Tissue expansions were performed in three patients with electrical scalp injury to reconstruct scalp alopecia, six months after the primary surgery (figure 7).

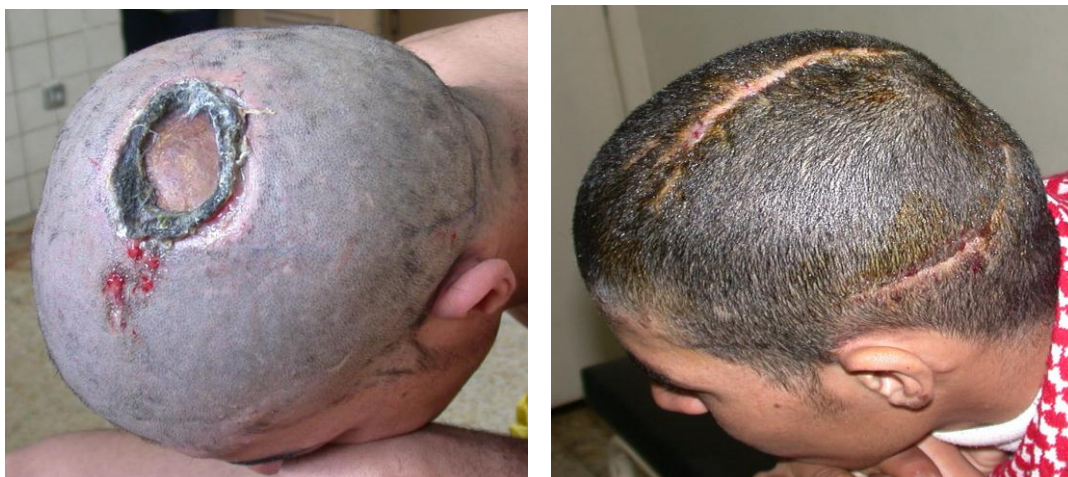**Table 2: Summary of results.**

| mechanism of scalp injury | Number of patients | Conservative treatment | Surgical intervention | complications    |
|---------------------------|--------------------|------------------------|-----------------------|------------------|
| Thermal burn              | 20                 | 16                     | 4 split skin graft    | Nil              |
| Electrical injury         | 10                 | Nil                    | 10 (scalp flaps)      | Infection (1pt). |

**DISCUSSION:**

Nearly all patients with thermal scalp burn were partial thickness in type, may be because (1): It is mostly caused by scald which is usually known to cause partial thickness burn. (2): Thick scalp. (3): Presence of hairs which act as a buffer neutralizing the burning agent. Scalp thermal burn is usually treated conservatively and heals with in 2-3 weeks by daily hydrotherapy with local application of silver sulfadiazine cream .Debridement of the electrically injured scalp with flap coverage with in 3<sup>rd</sup> to 5<sup>th</sup> day after injury, seems to be more appropriate to the patient than waiting for the settlement of the progressive necrosis, the unique effect of electrical current. It seems to be due to the presence of a little amount of muscle fibers at the vault, the most commonly affected site in our electrically scalp injured patients , in comparism to that present for example in extremities which necessitates frequent debridements before the definitive closure. It was found that the outer table was involved more than the whole thickness of the injured skull and this explain why decortication rather than craniectomy was performed first unless the inner table is clearly necrosed to avoid unnecessary bone resection which may necessitate cranioplasty later on. One may hesitate to do bone debridement at the skull suture lines, the sites where diploic vessels passing through. One should be careful and in most cases there was a little ooze because the diploic vessels are usually thrombosed and could be easily controlled with bone

wax. Surprisingly there was no damage to the meninges or to the brain even in- patients with high tension electrical scalp injuries in spite of the presence of a thick vault and the resistive hard fibrous sheath of dura matter which both are known to carry a high resistance to current flow. It may be attributed to the very short duration of contact with the electric source. A wider scalp flap is better to be planned than the required dimension to close a scalp defect, so that one can re-use it again if further bone debridement is required. Care should be taken to avoid inadvertent injury to the scalp arteries that lie just superficial to the galea. That is why a knife is preferred rather than electrocauterization for performing galea scoring to prevent potential thermal injury to these vessels<sup>(9)</sup> (figure 1:F). Hemostasis is important to avoid subgaleal hematoma , a common precursor of subgaleal abscess ,facial and periorbital cellulites and in its most extreme form, intracranial infection extending via the diploic vessels<sup>(8)</sup> .Replantation or free tissue transfer is the only available option for full thickness defects of the entire scalp<sup>(9,10)</sup> e.g. free vascularized omental transfer or Latissimus Dorsi muscle or myocutaneous flap<sup>(10)</sup> .Many electrical injuries, especially those occurring from contact with high-tension wires, occur at some height from the ground, so additional blunt trauma from a fall must be suspected specially skull fracture with or without underlying extradural hematoma and spinal injury.



**Figure2: Pre and postoperative views. Note the flap donor site was closed directly.**

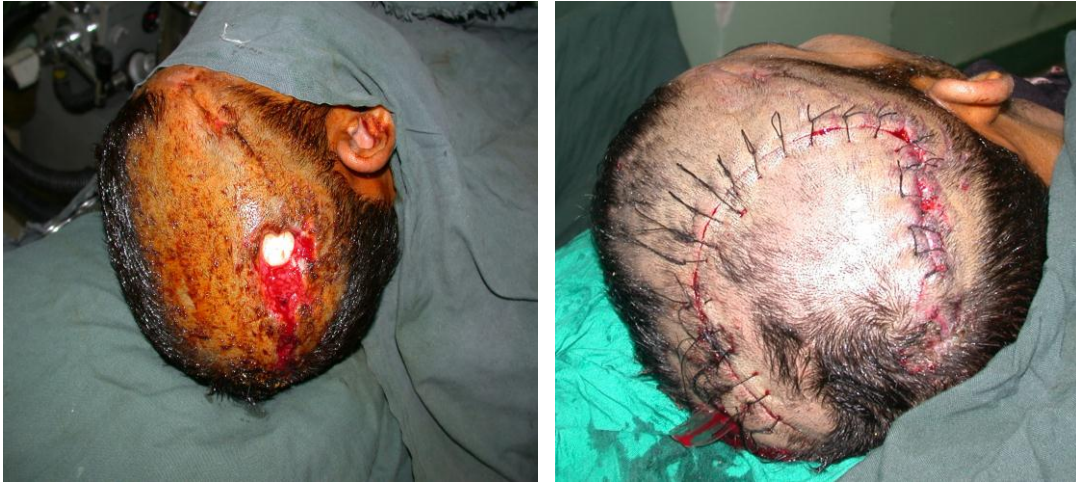

Figure 3: Pre and postoperative views of another patient with direct closure of flap donor site.

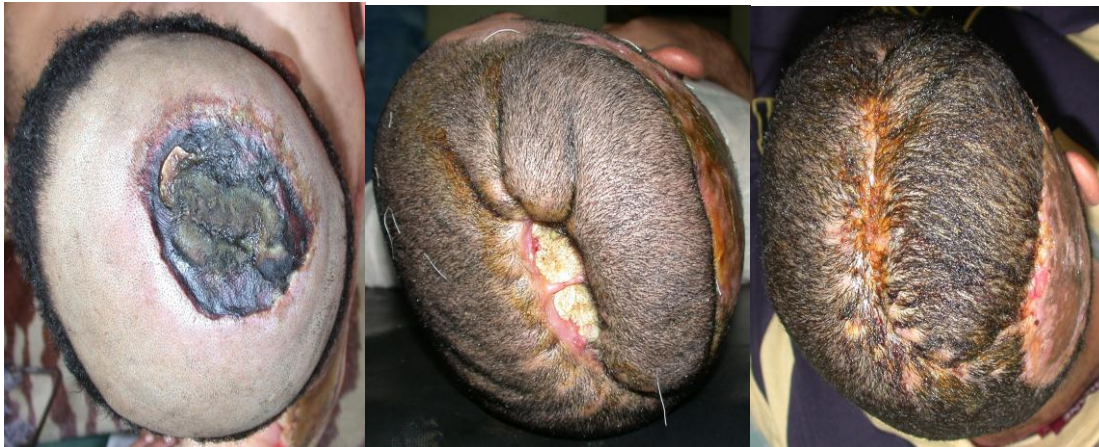


Figure 4: Lt View: Preoperative. Middle view: flap dehiscence with discharging pus. Rt view: Reinsertion of the same flap after adequate bone debridement and excessive galea scoring, 6 months postoperative view.

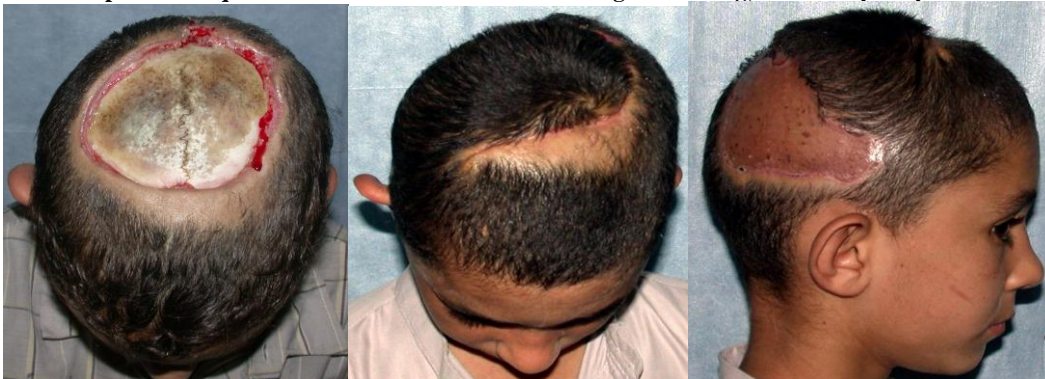

Figure 5: Lt view : Preoperative. Middle view: 2weeks postoperatively. Rt view: 6months postop. Note the well healed skin graft closing flap donor site.

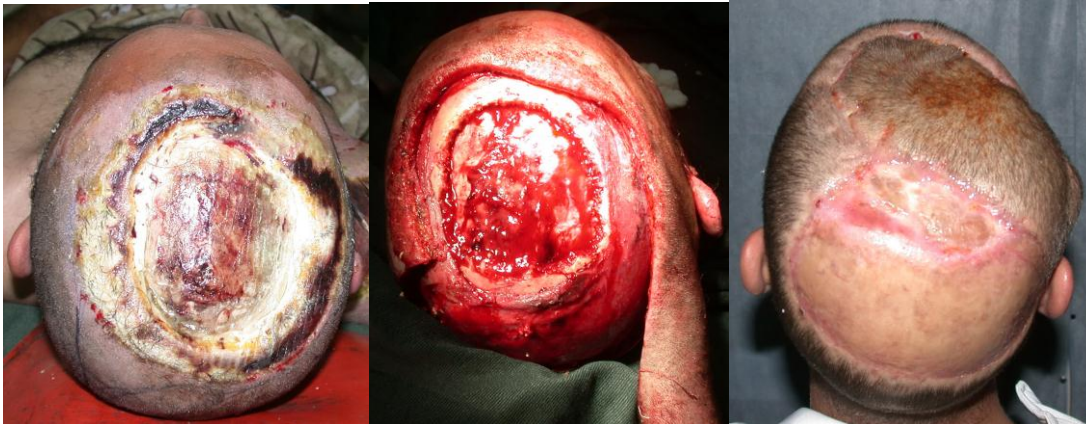


Figure 6: Same patient in figure 1.Lt view: Preoperative.Middle view: Operative view showing craniectomy site with flap elevation.Rt view: Two weeks postoperatively.

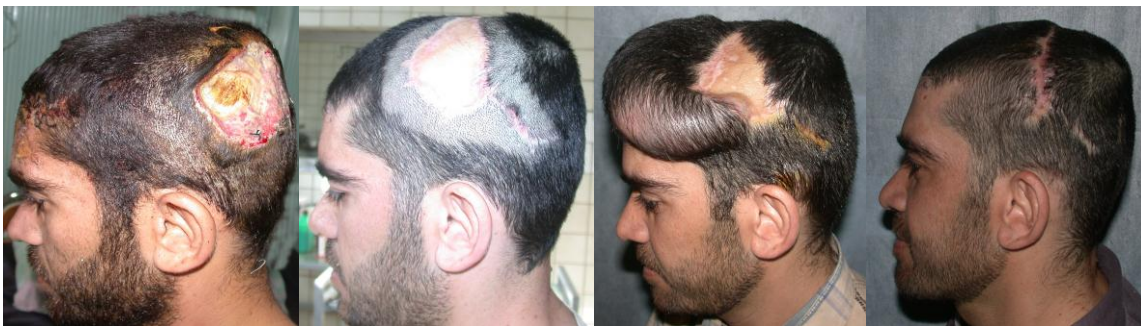

Figure 7: A: Preoperative view. B: local transpositional flap with skin graft coverage of flap donor site, 1month postoperatively. C: Tissue expansion 6 months later. D: Final result 8months later.

#### CONCLUSION:

Bone debridement with early local scalp flap coverage of electrically injured scalp is advisable to be performed as soon as possible after resuscitation. This has been found to reduce the risk of wound infection and decrease the length of hospitalization. One should not hesitate to debride any necrosed bone even that crossing suture lines. Appropriate galeal scoring is advisable to be done to any scalp flap to provide successful closure. Thermal scalp burns are mainly partial thickness in type best treated conservatively with minimal indication for surgical intervention.

#### REFERENCES:

1. John C McGregor: Critical care, Burns.Royal College of Surgeons of Edinburgh, Module Index, 2006.
2. Robert H: Mescellaneous thermal injuries. ACS Surgery, principles &practice, 2003.
3. Escudero-Nafs, Leiva-Oiiva, Collado-Aromir, Rabanal-Suirez, and De Molina-NOfiez.: High tension electrical burns, primary treatment of seventy patients, Annals of the MBC –1990; 3.
4. Mahesh H.Mankani and Raphael C.Lee: electrical injuries, Plastic Surgery Secrets, 1999:chapter 74,.

5. Barry Press: Thermal, Electrical and chemical injuries. Grabb and Smith's plastic surgery, fifth edition, 1997:chapter 16,.
6. Dennis P.Orgill and Julian J.Pribaz: Functional Reconstruction following Electrical injury. Annals of the New York Academy of Sciences (1999):888:96-104.
7. Babik, Sandor and Sopko: Electrical burn injuries, Annals of Burns and Fire Disasters – 1998, 11.
8. National electrical code internet connection.
9. Leedy, Jason E.; Janis, Jeffrey E.; Rohrich, Rod J.: Reconstruction of Acquired Scalp Defects: An Algorithmic Approach, Plastic and Reconstructive Surgery: 2005:116;15 September,.
10. Robert M.Freund: Scalp, Calvarium, and Forehead Reconstruction, Grabb and Smith's plastic surgery, fifth edition, 1997chapter 41,.