

# Histological and histomorphometric analysis of strontium chloride coated commercially pure titanium implant compare with hydroxyapatite coating

Ghasak H. Jani, B.D.S. <sup>(1)</sup>

Shatha S. Al-Ameer, B.D.S., M.Sc. <sup>(2)</sup>

Salam N. Jawad, B.D.S., M.Sc. <sup>(3)</sup>

## ABSTRACT

**Background:** In recent years, the immediate loading of dental implants has become more accepted as a standard protocol for the treatment of the edentulous area. Success in implant dentistry depends on several parameters that may improve phenomenon of osseointegration and new bone formation in close contact with the implant. The aim of study was to evaluate the effect of strontium chloride coating of screw shape commercially pure titanium dental implant osseointegration at bone - implant interface by histomorphometric analysis and compare with hydroxyapatite coating at 2 time periods (2 weeks and 6 weeks).

**Materials and methods:** Electrophoretic Deposition Technique (EPD) was used to obtain a uniform coating layer on commercially pure titanium screws. The tibia of 4 white New Zealand rabbits was chosen as implantation sites. Each tibia of rabbit received two screws, one strontium chloride coated and one hydroxyapatite coated and a total 30 histological sections were obtained for each coating material in each period of time. Histomorphometric analysis was performed to measure new bone formed ratio between implant and original bone, after 2 and 6 weeks healing periods.

**Results:** There was increased in new bone formation ratio for the strontium chloride coated implants than hydroxyapatite coated implants and over the two periods of time. There was an increase in the new bone formation ratio at bone-implant interface with time.

**Conclusion:** Coating commercially pure titanium implant with strontium chloride was more efficient in increasing osseointegration at bone implant interface than hydroxyapatite, which was demonstrated by higher new bone formation and maturation at the two periods of time 2 weeks and 6 weeks after implantation.

**Keywords:** Histomorphometric, commercially pure titanium, strontium chloride, hydroxyapatite. (J Bagh Coll Dentistry 2015; 27(1):26-31).

## INTRODUCTION

Implants are one of the most an important therapeutic surgical procedures providing both an aesthetic and functional alternative to tooth replacement. Procedures involving dental implants have grown steadily, rising consistently over the last 20 years to reach approximately one million performed annually worldwide. <sup>(1,2)</sup>

Dental implants vary in material, dimensions, geometries, surface properties and interface geometry, so today the dentist needs to select from more than 2,000 different dental implants and abutments in a specific treatment situation. <sup>(3)</sup>

The success of implant fixation is highly dependent on the implant surface properties to improve integration by different surface coating technologies for promoting osseointegration. <sup>(4)</sup> osseointegration was defined as a direct structural and functional connection between ordered living bone and the surface of a load-carrying implant.

In practice, this means that in osseointegration there is an anchorage mechanism where by nonvital components can be reliably and predictably incorporated into living bone and that this anchorage can persist under all normal conditions of loading. <sup>(5)</sup>

A relatively new anti-osteoporotic drug, strontium ranelate (protelos), is proposed to induce, in contrast to other anti-osteoporotic drugs (like bisphosphonate), simultaneously both an anti-resorption and bone forming effect. <sup>(6,7)</sup>

Strontium is a trace metal in human body and its physiologically stable divalent cationic form ( $\text{Sr}^{+2}$ ) The ion has a relatively high affinity to bone and may replace Ca in apatite crystals by ion exchange. Strontium ranelate contains two  $\text{Sr}^{+2}$  ions and ranelic acid. <sup>(8,9)</sup>

Histomorphometric measurement is a representative test in studying the nature of the implant-tissue surface and has been used by several authors to evaluate the bone implant interface. <sup>(10)</sup> Atsumi et al. categorize it as the method of highest reliability to evaluate implant stability that can be performed at any time (pre, intra or post) of the implantation. <sup>(11)</sup>

The purpose of this study was to make histological and histomorphometric analysis of strontium chloride ( $\text{SrCl}_2$ ) and hydroxyapatite

(1) Master Student. Department of Prosthodontics, College of Dentistry, University of Baghdad.

(2) Professor, Department of Prosthodontics, College of Dentistry, University of Baghdad.

(3) Pathologist. Ministry of Health, Baghdad, Iraq

(HA) coated implant, in rabbit tibia at 2 and 6 weeks implantation time.

## MATERIALS AND METHODS

### Specimens preparation

Eight screws shaped implants, 3.0 mm in diameter and 8mm in length (threaded part is 5mm and smooth part is 3mm) and pitch height is 1mm, were machined from commercially pure titanium rods grade 2 using Lathe machine, with slit in head of the implant to fit the screwdriver during insertion. The screws were washed in ethanol in an ultrasonic cleaner for 15 minutes and dried at 100°C for 15.

Four screws shaped implants were coated with strontium chloride for 4 min with 20 V and Sintering to 450 °C under inert gas (argon)<sup>(12)</sup> and the second group was coated with HA for 4min with 40 V and Sintering to 800 °C under inert gas (argon) according to **Hamed**<sup>(13)</sup>.



**Figure 1: Screws shaped implants**

### Animals and surgical procedures

Four healthy adult New Zealand rabbits of both sexes weighing 2 -2.5 kg were used. Antibiotic cover with oxytetracycline intramuscular injection was given to exclude any infection. Rabbit was left for two weeks in the same environment before surgical operation.

Each animal was weighed before operation to determine the required dose of anesthesia and antibiotic. Anesthesia was induced by intramuscular injection of ketamine hydrochloride (1ml/kg Body weight) and xylocaine 2% (1ml/kg B.W.). Tibia was shaved using shaving spray from medial side and skin was cleaned with ethanol. Later on the incision was made to expose the medial side of the tibia, the skin and fascia flap was reflected. Bone penetration was performed by Engine with straight hand piece (strong 90, Korea) with a round guide drill of 2.0mm in diameter to make hole with continuous cooling with normal saline. The enlargement of this hole was made gradually with drills then washed with saline to remove debris.

HA coated screws was placed in the hole using screw driver that fit the screw slit until 5mm of the screw was completely introduced into the

bone tissue and checked for stability. The Sr coated screw was placed within other hole.

Suturing of muscles was done with absorbable catgut suture followed by skin suturing with silk suture. The operation site was sprayed with local antibiotic (oxytetracycline spray), then long acting systemic antibiotic (oxytetracycline 0.5ml/kg B.W.). Postoperative care was performed by giving oxytetracycline antibiotic (local and systemic) for 3 days after surgery.

### Histological test

Four animals from each group were used for histological testing. Bone sectioning was performed while the animal was anesthetized with overdose of medication.

A disc cutter with low rotating speed and vigorous cooling was used for cutting the bone around the implant. Cutting was made 5mm away from the head of the implant to prepare a bone-implant block for histological study.

Bone-implant blocks were immediately stored in 10% freshly prepared formalin and left for overnight for fixation.

After fixation, bone decalcification was done by immersion the specimens in 10% solution nitric acid. In general, decalcification takes from 2 to 3 days. After that time the specimen was tested for complete decalcification by penetration of a narrow needle to the deepest part of the bone-implant block. A precipitant was formed if any amount of calcium is present. If any precipitate is formed, the acid solution covering the specimen should be changed. If no precipitate is detected it is assumed that the specimen is completely decalcified then the implant was gently removed from its bone bed.<sup>(14)</sup>

After complete decalcification, the bone-implant block was divided horizontally into two parts using a sharp scalpel with cross section of the implant inside the bone to be divided into two levels.

Dehydration of the specimen was done by immersing it in alcohol with serial concentration (70%, 80%, 90% and absolute alcohol remaining in each dish for one hour).

The specimens then were passed through two changes of xylene for 15-20 min. Each specimen was placed in a dish of melted paraffin and the dish was kept into a constant-temperature oven regulated to about 60° C during the course of several hours. The specimen was changed to two or three successive dishes of paraffin so that all of the xylene in the tissue was replaced by paraffin.

The specimens were moulded in the center of paraffin block, and adjusted to microtome where

serial sectioning with (4-5)  $\mu\text{m}$  of thickness for each section was performed and placed on a slide.

The slide was placed in a container having haematoxylin and eosin stain for 10 minutes to stain the tissue. Each bone implant block was divided into 2 levels and from each level 3 slides were obtained. Total of 30 sections were made for each coating material in each period of time.

By light microscope with SAMSUNG, GT-N7100 camera, Photographs of each section were taken at x4 power magnification and enlarged. The area of new bone was marked and measured using Image J software (NIH Image, National Institutes of Health, Maryland, USA)

The area of new bone was marked according to criteria stated by Shapiro, as look like coarse meshwork (trabecule bone) of pink tissue surrounding patches of much lighter or unstained tissue or matrix.<sup>(15)</sup>

The percent rate of new peri-implant bone formation (NBFR) was calculated using the following formula:<sup>(16)</sup>

$$\text{NBFR} = \frac{\text{area of newly formed bone}}{\text{total tissue area}} \times 100$$

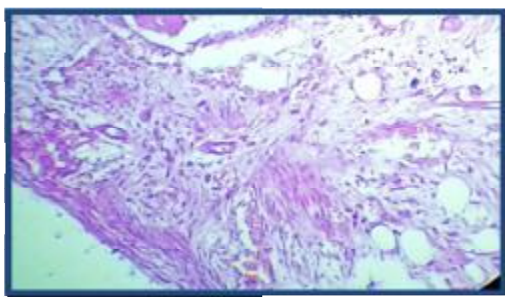
## RESULTS

### Clinical observation

All rabbits showed normal movement after one week which indicates that the rabbits tolerated the implantation, there was no sign of gross infection, tissue reaction. Screws could not be moved with manual force.

### Histological observations

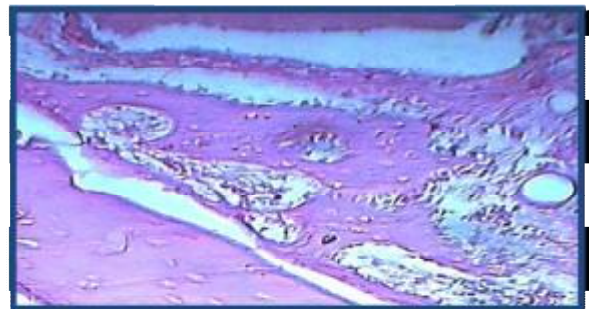
The histological feature of the implants coated with hydroxyapatite in rabbit tibia after two weeks of implantation showed osteoid tissue with numerous bone cell around with numerous new capillaries formation as shown in figure 2.



**Figure 2:** Microscopic photograph view of coated implant in rabbit tibia after two weeks of implantation, shows osteoid tissue with numerous bone cell around, (H&E stain) X10.

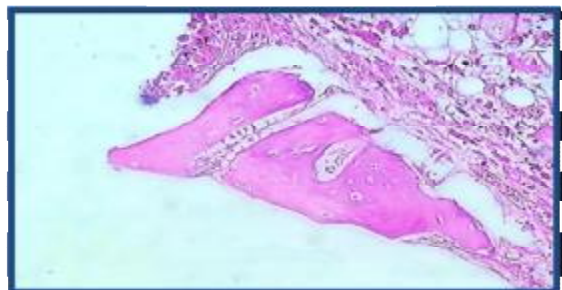Histological findings in the section of the tibia bone adjacent to the implanted cp Ti screws coated with SrCl<sub>2</sub> after 2 weeks of implantation

shows new bone trabeculae lined by osteoblast cell, osteoblast arranged as a rim of cells on the bone surface and active osteoid tissue as shown in figure 3.

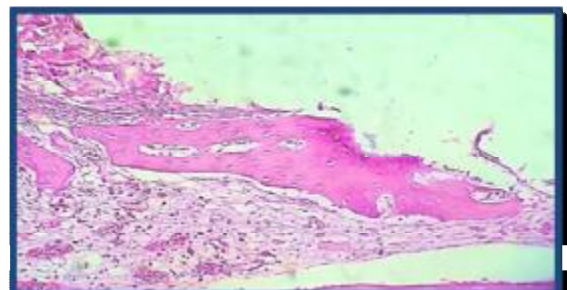


**Figure 3:** High magnification view of implant coated with SrCl<sub>2</sub> in rabbit tibia for two weeks duration shows new bone trabeculae (BT), lined by osteoblast cell (OBC). Note active osteoid tissue (AOT) formation around, H&E X10.

After 6 weeks, microscopic views showed new bone formation with osteocyte cells. Other higher magnification showed osteocyte cell irregularly distributed in thick trabeculae and a large number of osteoblast (Figures 4).

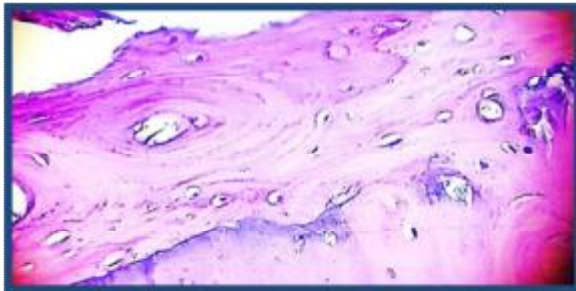


**Figure 4:** Microscopic photograph view for the HA coated Ti implant after 6 weeks of implantation shows new bone formation, osteocyte cell (OCC) and thick bone trabeculae. H&E X10.



**Figure 5:** Microscopic photograph view for the SrCl<sub>2</sub> coated Ti implant after 6 weeks of implantation shows new bone formation, numerous osteocyte cell (OCC) and thick bone trabeculae. H&E X10.

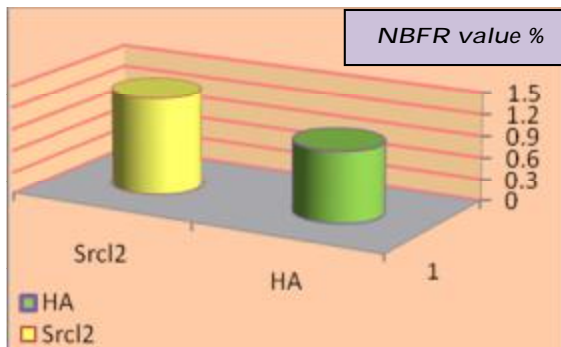
After 6 weeks of implantation, microscopic views for the section of the rabbit tibia bones surrounding the cp Ti implant coated with Srcl<sub>2</sub> showed active process of bone development, indicated by the active and large numbers of osteocyte cell clearly appeared (Figure 5). Higher magnification view showed clearly osteocyte cell, also reversal line (Figure 6)



**Figure 6: Microphotograph view for the old bone and new bone with reversal line around implant coated with Srcl<sub>2</sub> after 6 weeks of implantation. H&E X20.**

**Histomorphometric analysis Effect of strontium chloride coating at 2 weeks.**

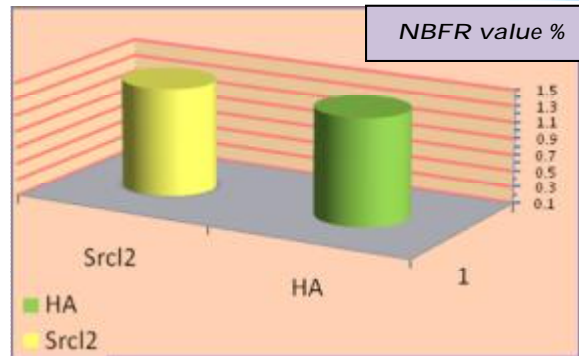
There was significantly increased new bone formation ratio for Srcl<sub>2</sub> coated implants than HA coated implants as seen in table 2 the mean value for HA and SrCl<sub>2</sub> after 2 weeks ( .9898 % ± .49161 and 1.3427 % ± .37322 ) respectively (Figure 7)



**Figure 7: NBFR value of srcl<sub>2</sub> coated implants and HA coated implants at 2 weeks interval.**

**Effect of strontium chloride coating at 6weeks**

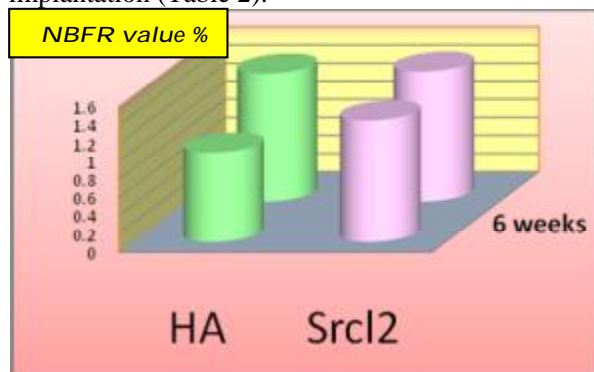
The strontium coated implants recorded a higher mean of new bone formation ratio than HA coated implants as seen in table 2 mean value for Srcl<sub>2</sub> coated implants after 6 weeks of 1.44 % ± .571, while for HA 1.419 % ± .565 (Figure 8).



**Figure 8: NBFR of srcl<sub>2</sub> coated implants and HA coated implants at 6 weeks interval.**

**Effect of time on removal torque value**

Both coating materials showed increased new bone formation ratio between 2 and 6 weeks of implantation (Table 2).



**Figure 9: The summary of the differences in the NBFR mean values between all groups.**

**Table 2: t –test for equality of means of NBFR for Srcl<sub>2</sub> and HA coated implants at 2 and 6 weeks intervals.**

Types	Time	t-test	df	P-value	Sig.
HA	2 weeks x 6weeks	2.522	29	0.017	S
Srcl <sub>2</sub>	2 weeks x 6weeks	0.662	29	0.513	NS

**DISCUSSION**

The rabbit is convenient for the study because it reaches skeletal maturity shortly after sexual maturity around 6 months of age. The physiology of rabbit cortical bone is accelerated when compared with human beings, rapid cortical bone remodeling allows for evaluation of osseointegration of dental implants as early as 6 weeks compared with 18 weeks in human. (17) The age of the present animals that used in this study was from 10-12 months thus assuring complete

closure of proximal tibial epiphysis, as stated by Pearce et al.<sup>(18)</sup>

The tibial sites in rabbit were chosen to mimic the clinical situation, since the dimension of this bone corresponds well with human alveolar space. Surgically this model provides low morbidity with easy access to the medial proximal tibia for implant placement.

#### **Effect of strontium chloride coating after 2 weeks of implantation**

Implants coated with SrCl<sub>2</sub> were shown to have a significantly larger bone area than the HA coated implants, which could be attributed to different mechanism of action. This was evidenced by the higher number of osteoblast and more bone trabecule and active ostiod than HA. **Ellis and Kathleen** explained the mechanism of action of Sr by enhancing replication of preosteoblastic cells by increased alkaline phosphatase activity.<sup>(19)</sup>

#### **Effect of strontium chloride coating after 6 weeks of implantation**

Bone formation ratio at 6 weeks was slightly higher in Sr than HA coated implants, 1.441, 1.419 respectively. However, the histological feature clearly showed the differences between them. More osteoblasts were seen which indicated the continuous bone formation, more osteocyte cells which reflected the higher maturation of the bone and more transformation of ostoblast to osteocyte in Sr section than in HA section. Reversal lines were also seen in sections of Sr implant sections while it was not seen in section of HA implant sections.

The approximation of ratio of Sr to HA may be due to decreasing amount of Sr from surface of implant due to high solubility of Sr (53.8 g/100 mL), moreover; amount of Sr coated on the implant was used compared to the ordinary dose of the drug administered to the osteoporotic patient (800 mg /kg /day).<sup>(20)</sup> The increased formation in the new bone for HA from 2 to 6 weeks might be due to delay activation of HA to osteoblast.

**Al-Duliamy** used (900 mg /kg /day) injection of SrCl<sub>2</sub> locally in palate for stabilization of expansion of rat palate after orthodontic treatment.<sup>(21)</sup>

#### **Effect of time on NBR**

Both Sr and HA coatings showed increased ratio of bone formed by time. HA coating showed significantly increased ratio of bone formation from 2 weeks to 6 weeks (0.98 % and 1.41% respectively) which indicated delayed activation

of HA to form new bone which was reflected by more bone formation at 6 than at 2 weeks

Sr coating showed non significant difference in the ratio of new bone formed as it was 1.34 % at 2 week and became 1.44 % at 6 weeks. This might indicate relatively constant activation of Sr to osteoblast through out the time period.

As conclusion; there was significantly higher new bone formation ratio of SrCl<sub>2</sub> coated CpTi implants than HA coated CpTi implant at 2 weeks healing period, also there was increased new bone formation ratio with time for both coating materials (HA and SrCl<sub>2</sub>) implants.

## **REFERENCES**

1. Susin C, Qahash M, Polimeni G, Lu PH, Prasad HS, Rohrer MD. Alveolar ridge augmentation using implants coated with recombinant human bone morphogenetic protein-7 (rhBMP-7/rhOP-1): histological observations. *J Clin Periodontol* 2010; 37: 574-81.
2. Le Guéhennec, Soueidan A, Layrolle P, Amouriq Y. Surface Treatments of Titanium Dental Implants for Rapid Osseointegration. *Dent Mater* 2007; 23(7): 844-54.
3. Jokstad A, Braegger Urs, Brunski JB, Carr AB, Naert L, Wennerber A. Quality of Dental Implants. *Int J Prosth.* 2004; 17:607-641.
4. Chaïy R, Qing Li, Wei Li, Appleyard R, Swain M. Effect of fully porouscoated (FPC) technique on osseointegration of dental implants. *Adv Mater Res.* 2008; 32:189-192. (IVSL).
5. Branemark PI. The Branemark Novum protocol for same-day teeth. A global perspective. Chicago: Quintessence; 2001. p. 9-29.
6. Blake GM, Fogelman I. Strontium ranelate: a novel treatment for postmenopausal osteoporosis: a review of safety and efficacy. *Clin Interv Aging* 2006; 1(4):367-75.
7. Pors Nielsen S. The biological role of strontium. *Bone.* 2004; 35(3): 583-8.
8. Morohashi T, Sano T, Harai K, Yamada S. Effects of strontium on calcium metabolism in rats. II. Strontium prevents the increased rate of bone turnover in ovariectomized rats. *Jpn J Pharmacol* 1995; 68(2):153-9.
9. Boivin G, Meunier PJ. The mineralization of bone tissue: a forgotten dimension in osteoporosis research. *Osteoporos Int.* 2003; 14 Suppl 3: S19-24.
10. Meredith N. On the clinical measurement of implant stability and osseointegration, A PhD thesis. Sweden: Department of Biomaterials, University of Go`teborg, 1997:1-209.
11. Atsumi M, Park S, Wang H. Methods used to assess implant stability: Current status. *Int J Oral Maxillofac Implant* 2007; 22(5): 743-54.
12. Jani GH. Torque removal test of strontium chloride and hydroxyapatite coated commercially pure titanium implant complemented with histomorphometric analysis (a comparative Study). A master thesis, College of Dentistry, University of Baghdad, 2014.

13. Hamad TI. Histological and Mechanical Evaluation of Electrophoretic Bioceramic Deposition on Ti- 6Al-7Nb Dental Implants, A Ph.D. thesis, College of Dentistry, University of Baghdad, 2007.
14. Bhaskar SN. Orban's Oral Histology and Embryology. 11<sup>th</sup> ed. USA: Mosby, 1991.
15. Shapiro F. Bone development and its relation to fracture repair. The role of mesenchymal osteoblasts and surface osteoblasts. Eur Cell Mater 2008;15:53-76
16. Baek SM, Kim SG, Lim SC. Histomorphometric Evaluation of New Bone Formation around a Magnetic Implant in Dogs. Implan 2011;15(1): 22-30. (IVSL).
17. Michaels OC, Carr AB, Larsen PE. Effect of prosthetic superstructure accuracy on the osseointegrated implant bone interface. Oral Surg Oral Med Oral Path 1997; 83(2):198-205.
18. Pearce A, Richards ARG, Milz S, Schneider E, Pearce SG. Animals Models For Implantation Biomaterial Research In Bone: A review. Euro Cells Mater 2007; 13:1-10.
19. Ellis E. Golub and Kathleen Boesze-Battaglia. The role of alkaline phosphatase in mineralization. Curr Opin Orthop 2007; 18: 444-8.
20. Ammann P, Shen V, Robin B, Mauras Y, Bonjour JP, Rizzoli R. Strontium ranelate improves bone resistance by increasing bone mass and improving architecture in intact female rats. J Bone Miner Res 2004; 19: 2012-20.
21. Al-Duliamy M. The effect of orthodontic relapse on the proliferation of fibroblast and epithelial rests of Malassez in periodontal ligament of rat molars (A histopathological study). A master thesis, Collage of Dentistry, University of Baghdad, 2011

### الخلاصة

**مقدمة:** في السنوات الأخيرة، أصبح تحميل الفوري لزراعة الأسنان أكثر بروتوكول قبولاً للعلاج منطقة الخالية من اسنان. النجاح في زرع الأسنان يعتمد على عدة عوامل التي قد تحسن ظاهرة الاندماج العظمي و تكوين عظام جديدة على اتصال وثيق مع الزرعات وكان الهدف من الدراسة هو تقييم تأثير طلاء كلوريد السترونتيوم لغرسات الاسنان المصنوعة من التيتانيوم النقي التجاري على الاندماج العظمي لغرسات في العظم عن طريق تحليل القياس النسيجي ومقارنتها مع طلاء هيدروكسيباتيت في فترات زمنية ( 2 أسابيع و 6 أسابيع).

**المواد و طرق العمل:** تم استخدام تقنية الترسيب الكهربائي ( EPD ) للحصول على طبقة طلاء موحد على زرعات الاسنان المصنوعة من التيتانيوم النقي تجارياً وقد تم اختيار الساق من 4 الأبيض أرانب نيوزيلندا كمواقع زرع . كل من الساق أرنب تلقى اثنين من البراغي ، واحدة مطلية بـكلوريد السترونتيوم و احدة مطلية بهيدروكسيباتيت وتم الحصول على ما مجموعه 30 المقاطع النسيجية لكل مواد الطلاء في كل فترة من الزمن .تم إجراء تحليل القياس النسيجي لقياس نسبة العظم الجديدة المتكون بين الزرع و العظام الأصلية، بعد 2 و 6 أسابيع من فترات الشفاء

**النتائج:** الغرسات المطلية بـكلوريد السترونتيوم اكثر كفاءة بزيادة تكوين العظم من الغرسات المطلية بهيدروكسيباتيت خلال الفترتين من الزمن .كانت هناك زيادة في نسبة تكوين العظم في منطقة التقاء العظم والغرسه مع مرور الوقت.

**الاستنتاج:** كان طلاء التيتانيوم النقي تجاري بـكلوريد السترونتيوم أكثر كفاءة في زيادة الاندماج العظمي في منطقة التقاء العظم والغرسه من هيدروكسيباتيت ، الذي يتضح من تكوين العظام الجديدة أعلى نسبة واكثر نضجاً في الفترتين 2 أسابيع و 6 أسابيع بعد الزرع.