



## Oral –Periodontal Findings of Langerhans Cell Histiocytosis (Case Report)

Bashar H Abdullah <sup>(1) \*</sup>

Basima Gh. Ali <sup>(2)</sup>

Ameena Rehan <sup>(3)</sup>

Omar Sh Musside <sup>(4)</sup>

Hanaa Jawad <sup>(5)</sup>

<sup>(1,3,4)</sup> Department of Oral Diagnosis, College of Dentistry, Baghdad.

<sup>(2)</sup> Department Of Periodontics, College Of Dentistry, Baghdad.

<sup>(5)</sup> Ministry Of Health, Baghdad, Iraq.

### Article Info:

#### -Article History:

-Received: 31/7/2022

-Accepted: 6/9/2022

-Available Online:

Jun, 2023

### Keywords:

histiocytosis, LCH, oral neoplasm, gingival recession, eosinophils

©2023 COLLEGE OF DENTISTRY  
TIKRIT UNIVERSITY. THIS IS AN OPEN  
ACCESS ARTICLE UNDER THE  
CC BY LICENSE

<https://creativecommons.org/licenses/by/4.0/>



### \*Corresponding Author:

#### Email:

Dr.basimaali@gmail.com

Department Of Periodontics,  
College of Dentistry,  
Baghdad.

### Abstract

Langerhans cell histiocytosis is a rare disease related to aggressive proliferation of histiocytes that could be a multisystem involvement disease. The diagnosis is based on the histopathological finding. Oral findings should carefully be considered when extensive periodontal involvement is seen in comparison to marginal periodontitis.

## Introduction:

Langerhans cell histiocytosis (LCH), previously famed as histiocytosis X, is a neoplasm of hematological background affecting young children and even infants. The incidence is about 0.5-5.4 cases /million person per year (1). It is distinguished histologically by a rapid

monoclonal increase of histocyte resemble cells (Langerhans cells), accompanied by different numbers of eosinophils, plasma, lymphocytes cells and multinucleate giant cells (2). The histopathological examination of LCH gives the definite diagnosis supported by

immunohistochemistry (CD 1A). Oral involvements are not uncommonly it may be the early manifestation in this condition. Generally, the nonspecific pattern of the early symptoms, may be cause of a misdiagnosis (3). The aim of this case report is to highlight on the role of dentist to early diagnose such cases for better prognosis.

### Case presentation

A 22-year-male attend the department of periodontology, College of Dentistry /University of Baghdad, with the chief complaint of sever gingival recession Fig. (1), halitosis and sensitivity of lower and upper molars since two years ago. Past dental history revealed that the patient attended a private dental clinic for several times, however the condition didn't improve with all analgesics and antibiotics that were given. The patient had no history of any trauma and anon significant medical and family history. the patient is smoker and alcoholic. Intra oral examination reveals multiple gingival and mucosal lesions with irregular and punched out bony destruction associated maxillary and mandibular molars regions. The gingiva is tender to palpation and the accused teeth are highly sensitive, with sever loss of attachments and about 5-6 mm gingival recession measured from CEJ to the gingival margin. Other oral signs include, gingival enlargement, mobility of molar teeth in addition to pain within jawbone.

A provisional diagnosis was made with respect to the severity of clinical attachment loss, pocket depth and bleeding on probing as localized periodontitis stage II grade C currently stable, smoker (4). Since the patient didn't response to conventional periodontal treatment that include scaling root planning and local application of desensitizing agents, a decision was made to do a biopsy for histopathologic examination. Following a visit of thorough scaling, a biopsy was taken from the most sever sits under local anesthesia. Histopathological examination revealed a heavy mononuclear infiltrate of

histiocytic cells admixed with eosinophil's and scattered giant cells Fig. (2) a diagnosis of Langerhans cells histiocytosis. The patient referred to hematologist to assess bone and visceral involvement.

Brain CT and PET-CT scan revealed evidence of left temporal and left parietal bones bony lytic lesion with beveled edges in addition to ill- defined lytic sclerotic intramedullary lesions in bilateral distal femora and proximal tibiae. Pet-CT revealed also minimally hypermetabolic inactive 3mm pleural based nodule in the left lower lobe lung. This gave an ultimate diagnosis of systemic involvement of LCH. A correlation was made depending on the clinical and histopathological findings. For further treatment, the patient was referred to cancer hospital.

### Discussion:

The LCH lesion in maxillofacial region possess a relative frequency of about 20% and the oral manifestation may be the earliest clinical signs of this condition and in a lot of cases the mandible may be the only sites affected. These lesions are mainly in the gingiva, hard palate, and floor of the mouth (5). The incidence of LCH oral lesions may reach up to 70 % (6). The jaws are involved twice as frequently as the oral soft tissues' lesions. Periodontal lesions – identified in about (80-90) % of published cases these include: gingival recession (caused by periodontal inflammation), bone resorption and clinical attachment loss with deep periodontal pockets, etc. As a result of bone loss, the teeth resemble "floating teeth", and premature loss of teeth is possible (7).

The Mucosal lesions that include round ulcerative lesions, with erythematous borders that is inflamed, and painful upon palpation and probing, usually on the buccal mucosa, these mucosal findings in the present study are similar to the findings of other case reports (6).

Bone lesions whether single or multiple are the most prevalent clinical findings seen in the majority of cases. Among

bones (other than the jaws) that involved in are skull bones especially the orbital and temporal bone in addition to the vertebrae (8).

There is pathological inclusions of Langerhans cells within different organ systems of body such as bones and bone marrow, skin, lung, brain, in addition to lymph nodes, liver, spleen, and endocrine (9).

### Conclusion:

The LCH disease is of clinical importance to dental professionals because commonly involves the oral and maxillofacial region and early symptoms can be manifested in the jaw. The oral findings are the basis for diagnosis of LCH that confirm by histopathological examination to overcome any mistaken with common dental problems such as periodontal and periapical lesions. Thus, combined oral findings have to be neatly diagnosed and investigated by the dentist to revoke the systemic embroilment, as the oral cavity is the mirror of most systemic diseases. The periodontal management of those patients must include implementation of good oral hygiene measures with rigorous scaling and root planning. extraction of teeth depend on the mobility and response to treatment. Consultation with other specialist is of great importance especially with multisystem involvement.

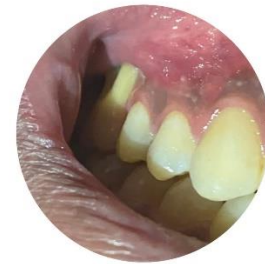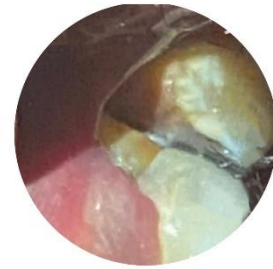

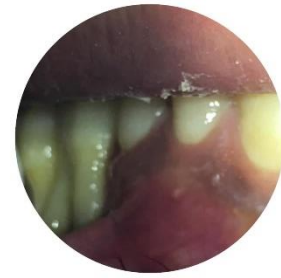
Fig. (1): Intra oral gingival lesion associated molar teeth.

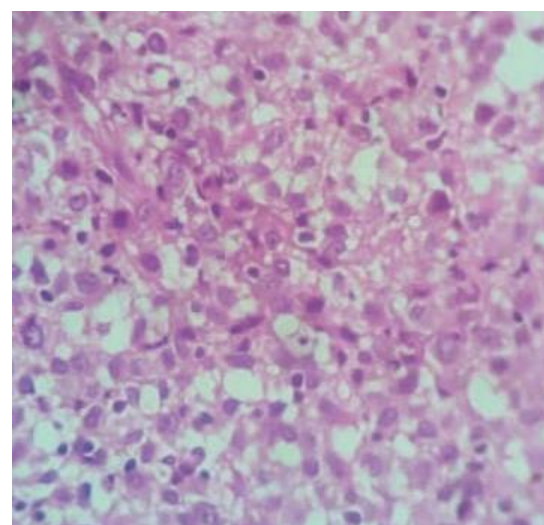


Fig. (2): Histopathological findings reveals diffuse infiltrate of Langerhans cell with eosinophils (H&E stain, x40)

## References:

1-Hyery Kim, MD,Ye-Jee Kim,Juhee Shin,SoyoonMIN, MD,Sung Han Kang, MD  
Analysis of the Incidence and Diagnostic Pattern of Langerhans Cell Histiocytosis from the Population-Wide Healthcare Database in Korea,Blood (2019) 134 (Supplement\_1): 4866.<https://doi.org/10.1182/blood-2019-131531>

2-Shweta Bansal, Arun Garg, and Richa Khurana  
Langerhans Cell Histiocytosis – A Challenge for the Dental Professional  
J Cutan Aesthet Surg. 2017 10(4):215218.doi: 10.4103/JCAS.JCAS\_66\_17

3. Greenberg MS, Glick M, Ship JA. Burket's Oral Medicine. 11th ed. Hamilton: BC Decker; 2008. pp. 144-5.

4- Papanou P N, Sanz M, Buduneli N et al.  
Periodontitis: Consensus report of workgroup 2 of the 2017 World Workshop on the Classification of Periodontal and Peri-Implant Diseases and Conditions. J Clin Periodontol 2018; 45 Suppl 20: S162–S170.

5- Faustino ISP, Fernandes PM, Pontes HAR, Mosqueda-Taylor A, Santos-Silva AR, Vargas PA, Lopes MA . Langerhans cell histiocytosis in the oral and maxillofacial region: An update.J Oral Pathol Med. 2021;50(6):565-571. doi: 10.1111/jop.13207.

6-Assya Krasteva, Elena Obreshkova, Hristina Michaylova, Evgeny Al ,Angelina Kisselova & Zahary Krastev  
Oral Cavity and Systemic Diseases—Langerhans Cell Histiocytosis  
Biotechnology & Biotechnological Equipment 2012. ISSN: 1310-2818 (Print) 1314-3530  
<https://doi.org/10.5504/BBEQ.2012.0105>

7- Arzu Pinar Erdema/Yelda Kasimoglu/Elif Sepetç/Koray Gencay/Songul Sahind/  
Sergulen Dervisoglu  
Oral Manifestations May Be the First Sign of Langerhans Cell Histiocytosis  
Article in Oral Health & Preventive Dentistry · 2013.vol 11,no 1,Pp57-59  
DOI: 10.3290/j.ohpd.a29376 ·

8. Eman Hussein Hammouri, Hala Antoun Sweidan, Omar AShokaibi, Leen Al Omari  
Langerhans cell histiocytosis: A case report with oral manifestations and the role of pediatric dentists in the diagnosis.Clinical Case Reports. 2020.;00;1-5  
DOI: 10.1002/ccr3.2726Free PMC article

9- Samar Mahmood , Mohammad Raza , Khushboo Nusrat , Shayan Marsia , Awais Abbas  
Infiltrating the Heart and Kidney: A Rare Pediatric Case of Multisystem Langerhans Cell Histiocytosis from Pakistan Cureus .2019 ,Mar; 11(3): e4315.