

Original paper**Correlation between Time Elapsed after Maxillary Teeth Extraction and Maxillary Sinus Pneumatization**Ali S. Al-Haddad^{^*}[^] Department of Oral Diagnosis, College of Dentistry, Karbala University, Karbala, Iraq.**Abstract**

B **background:** Pneumatization is an activity that occur physiologically in all paranasal sinuses during the growing period, causing them to increase in volume. Pneumatization of the sinus after extractions can have various treatment-planning implications, such as reduction of the alveolar bone height available for implants, orthodontic miniscrew or complication in preprosthetic surgery.

Aim of the study: To find the correlation between rate of pneumatization of maxillary sinus and time after extraction of the related teeth.

Subjects, material and methods: A total of 96 panoramic radiograph used to measure the supero-inferior differences of the sinus floor position by using interorbital line and 2 zygomatic lines as a reference lines after one to more than 10 years of the unilateral extraction of one of the maxillary second premolar, first molar or second molar tooth of 48 experimental subjects to make a comparison with the contralateral 48 control subjects with bilateral present mentioned teeth.

Results: 48 control subjects show no statistically significant mean difference between the one side and the adjusted contralateral side. There was statistically significant increase in the side of the missing tooth compared to that of the contralateral side. The site of the missing tooth is associated with an average increase in distance of 2.53mm from the comparable 0.22mm in the control subjects, and this change was statistically significant. There is a moderate strong positive linear correlation coefficient between time interval and maxillary sinus pneumatization $r=0.45$ $P<0.001$.

Conclusion & discussion: The pneumatization of the maxillary sinus is related to the time interval since extraction. The longer the time interval the more maxillary sinus pneumatization.

Key words: maxillary sinus, pneumatization, panoramic radiograph, posterior teeth.

Introduction

Pneumatization is an activity that occurs physiologically in all paranasal sinuses during the growing period, causing them to increase in volume. ^(1, 2)

The maxillary sinuses are air-containing spaces that occupy maxillary bone bilaterally. They are the first of the paranasal sinuses (e.g., maxillary, ethmoid, frontal, and sphenoid) to develop primitively and begin in the third month of fetal development as mucosal invaginations or pouching of the ethmoid

infundibula. ^(3,4) The initial maxillary sinus development, also termed primary pneumatization, progresses as the invagination expands into the cartilaginous nasal capsule. ⁽⁵⁾

Secondary pneumatization begins in the fifth month of fetal development as the initial invaginations expand into the developing maxillary bone. After birth, the maxillary sinus expands by pneumatization into the developing alveolar process and extends anteriorly and inferiorly from the base of the skull, closely matching the growth rate of the

*For Correspondence: E-Mail aliselmanalhaddad38@gmail.com

maxilla and the development of the dentition.⁽⁶⁾ As the dentition develops, portions of the alveolar process of the maxilla, vacated by the eruption of teeth, become pneumatized.² By the time a child reaches age 12 or 13 years, the sinus will have expanded to the point at which its floor will be on the same horizontal level as the floor of the nasal cavity. In adults, the apices of teeth may extend into the sinus cavity and can be identified in anatomic specimens or through computed tomography (CT) imaging⁽⁷⁾

Expansion of the sinus normally ceases after the eruption of permanent teeth, but on occasion, the sinus will pneumatize further, after the removal of one or more posterior maxillary teeth, to occupy the residual alveolar process. In many of the cases, the sinus often extends virtually to the crest of the edentulous ridge. The maxillary sinus is significantly larger in adult patients who are edentulous in the posterior maxilla compared with patients with complete posterior dentition⁽⁸⁾. The reasons for sinus pneumatization are poorly understood. There is many factors influence this process including hereditary,^(1, 9) craniofacial configuration⁽¹⁰⁾, growth hormones⁽¹⁰⁾, sinus air pressure^(2, 11, 12), density of the bone⁽¹⁰⁾, and sinus surgery⁽²⁾. The cause for this phenomenon, also referred to us the forth expansion phenomenon of the maxillary sinus,⁽¹³⁾ has been explained as a type of disuse atrophy^(14,15)the decrease of function forces transferred to the bone after tooth loss causes a shift in the remodeling process toward bone resorption according to Wolf's law⁽¹³⁾. This results in an increase of the sinus volume at the expense of the edentulous alveolar ridge. The rate and degree of the pneumatization process after tooth loss may be influences by

1. The protrusion of tooth roots into the sinus cavity⁽¹⁴⁾. Roots that protrude into the sinus have a thin cortical bone lining⁽¹⁶⁾. During extraction this thin bone may break and dislocate, thus allowing the sinus to expand toward the empty socket.

2. Molar extraction. Greater pneumatization has been found after molar extraction in comparison to premolar extraction⁽¹⁴⁾. The reason may be the large defect left in the alveolar bone after molar extraction, which require a longer healing time, thus allowing the sinus to pneumatize.
3. Because initially the mandibular height is twice that of the maxilla, maxillary bone loss is also significant in the long-term edentulous patient.⁽¹⁷⁾

Pneumatization of the sinus after extractions can have various treatment-planning implications, such as reduction of the alveolar bone height available for implants⁽¹³⁾ or complication in preprosthetic surgery⁽¹⁸⁾. In this study we discuss the maxillary sinus behavior following years of posterior teeth extraction.

Subject, Materials and Methods

In the present prospective study a 96 panoramic radiograph from 96 subjects were used. The patients had no history of sinus and nasal disease, sinus surgery, sinus pathology of a dental cause or upper posterior teeth super eruption, 48 control subjects who had a bilateral present upper second premolar, first molar and second molar, with age mean (33.95) and mode (17), and 48 experimental subjects with age mean (37.16) and mode (17) who had extracted unisided one of the upper second premolar, first molar or second molar. The male-female ratio was the same (24 male and 24 female) to avoid gender bias.

All panoramic radiographs were taken by the same digital panoramic machine (planmeca Promax, Helsinki, Finland) with 68 kV, 10 mA and 16 second exposure time.

We put three digital reference lines(0.1 thickness) by using planmeca Romexis software 3.1.1.R to measure the vertical distance between them as described by Packota et al⁽¹⁹⁾, Xie et al⁽²⁰⁾ and Arbel Sharan and David Madjar⁽²¹⁾. An

interorbital line joining the lowest points of two orbital rims and two zygomatic process lines passing through the lowest brim of the zygomatic process on each side of the jaw matching to the interorbital line as shown in figure (1).

By using horizontal line in the panoramic software in relation to the interorbital line, any difference between them more than 5 degree that radiograph excluded to avoid inaccuracy.⁽²⁰⁾

In this study we measured the distance between the interorbital line and the zygomatic process line and the distance between the interorbital line and the maxillary sinus floor over either the second premolar, first molar, or second molar, which are the closest to the sinus.^(22, 23, 24)

In the experimental subjects we measured the vertical distance between the interorbital line and the lowest point of the maxillary sinus floor in the site of the missing tooth and the contralateral present tooth site (IS). Also we measure the vertical distance between the interorbital line and the zygomatic process line (IZ) in the two sides of the jaw, which aid to calculate the ratio of distortion between two side that result from head tilting during taking panoramic radiograph to the subjects.^(20,25)

Each experimental subject has a comparable control subject. they have the same age group , gender and the site/side of the missing tooth in which the site of the missing tooth become a nominal even he/she don't have a missing tooth.

The null hypothesis was made as $IS_X/IZ_X=IS_T/IZ_T$.⁽²¹⁾ Where X representing the missing tooth side, and T represents the contralateral present tooth side. The superoinferior differences of the sinus floor position between the side of the missing tooth and the side of present tooth was represent by the calculation $IS_X-(IS_T*IZ_X/IZ_T)$. A positive value point to a more inferiorly situated sinus floor on the side of the missing tooth.

We were grouping the age of subjects into three groups, group 1: (15-29yr), group 2: (30-44yr), group 3: (45-59yr) to make an approximate experimental-control subjects age. We were depending on the memory of the experimental subject about time elapsed after extraction of the tooth in years and divided them into three group, group 1: (1-2yr), group 2: (3-9), group 3: (10- more) for easy discussion of the effect of time elapsed after extraction.

Results

Table 1 show that there was no statistically significant mean difference between the one side and the adjusted contralateral side in the control subjects.

There was a significant increase in the side of the missing tooth compared to that of the contralateral side. The site of the missing tooth was associated with an average increase in distance of 2.53mm from the comparable 0.22mm in the control subjects, and this change was statistically significant.

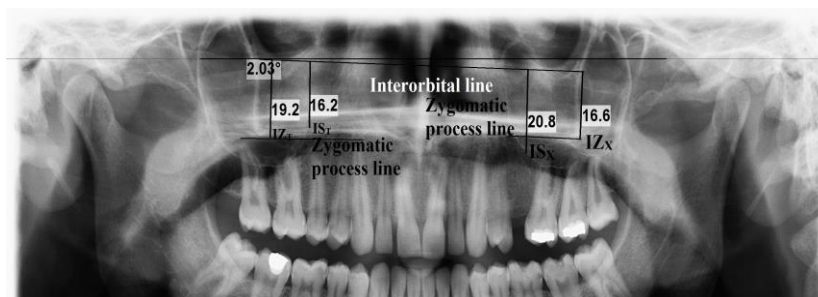


Figure 1. Panoramic radiograph showing the reference lines and all measurements that done

Table 1. The case-control difference in mean supero-inferior differences of the sinus floor position between the side of the missing teeth and the contralateral side (mm).

	Distance between the interorbital line and the maxillary sinus floor superior to the missing tooth root (mm)	Adjusted distance on the contralateral side with full maxillary dentition (to IZx:IZt ratio)	The supero-inferior differences of the sinus floor position between the side of the missing teeth and the contralateral side (mm)	P (paired t-test)
Control (full maxillary molar and premolar dentition)				0.5[NS]
Range	(15.7 to 35.5)	(16.35 to 37.5)	(-5.05 to 5.45)	
Mean	25.13	24.92	0.22	
SD	5.24	5.8	2.2	
SE	0.756	0.837	0.318	
N	48	48	48	
Case (with missing maxillary molar or premolar tooth)				<0.001
Range	(20.4 to 38.6)	(14.2 to 34.2)	(-2.84 to 10.53)	
Mean	26.29	23.76	2.53	
SD	4.14	3.86	2.57	
SE	0.597	0.557	0.37	
N	48	48	48	
P (independent samples t-test for case-control difference)			<0.001	

Figure 2 show the case-control difference in mean which represent the imbalance between maxillary sinus height above the missing tooth in cases subjects and the maxillary sinus height above the comparable control side (which is a randomly and non-side prepossession differences) and this imbalance was obvious and statistically significant. the mean supero-inferior differences of the sinus floor position between one side and the contralateral side are 0.22mm in full maxillary dentition, it increase to 1 after 1-2 year since extraction, and to 2.47mm after 3-9 years interval, and become 4.19mm above 10 years and above as shown in table 2 and figure 3.

The pneumatization of the maxillary sinus is related to the time interval since extraction. The longer the time interval the more maxillary sinus pneumatization. And this difference is statistically significant, and there is a moderate strong positive linear correlation coefficient between time interval and maxillary sinus pneumatization $r=0.45$ $P<0.001$.

Table 3 shows that age of patient is not prevalent agent on pneumatization of the maxillary sinus, while time since extraction increases it toward the site of extracted related teeth in an average of 0.23mm in each year.

Discussion

The pneumatization of the maxillary sinus after posterior teeth extraction has been as mentioned by the present study and other studies, ^(26 - 30). In this study we have followed the rate of that pneumatization after one to more than ten years of that extraction, see figure 4 and 5.

the Panoramic radiographic techniques used in this work because it provide an excellent overview assessment of underlying bony structure and pneumatization of the maxillary sinus.^(31,32), we have followed the measurements described by Packota et al⁽¹⁹⁾ and Arbel and David⁽²¹⁾.

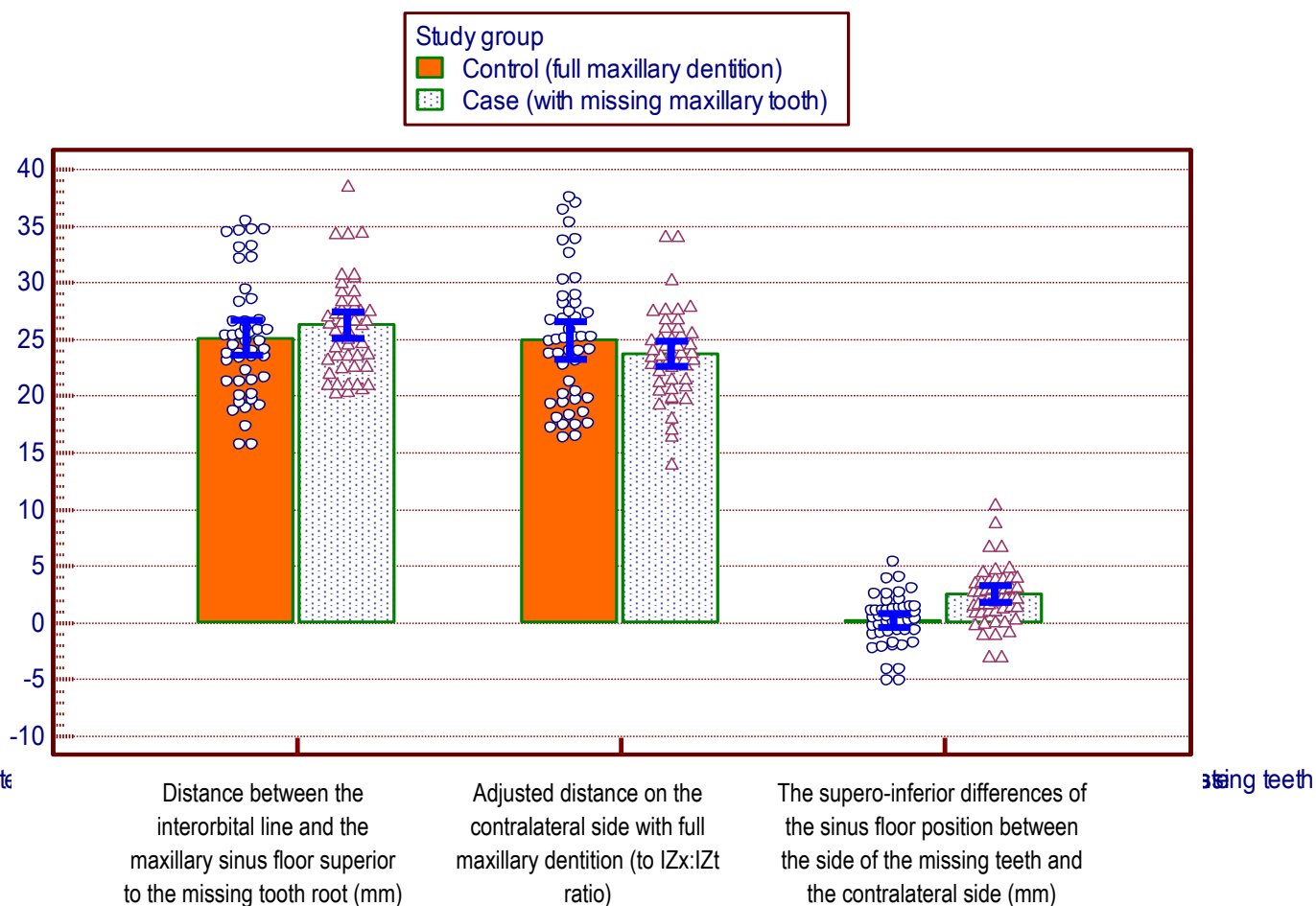


Figure 2. Dot diagram with error bars showing the case-control difference in mean (with its 95% confidence interval) supero-inferior differences of the sinus floor position between the side of the missing teeth and the contralateral side (mm).

Table 2. The mean supero-inferior differences of the sinus floor position between the side of the missing teeth and the contralateral side (mm) by time since extraction.

	Time in years since extraction-groups				P (ANOVA trend)
	Control (No missing tooth)	1-2	3-9	10+	
The supero-inferior differences of the sinus floor position between the side of the missing teeth and the contralateral side (mm)					<0.001
Range	(-5.05 to 5.45)	(-2.84 to 4.98)	(-0.94 to 6.9)	(1.12 to 10.53)	
Mean	0.22	1	2.47	4.19	
SD	2.2	2.5	2.05	2.93	
SE	0.318	0.753	0.401	0.885	
N	48	11	26	11	

r=0.45 P<0.001

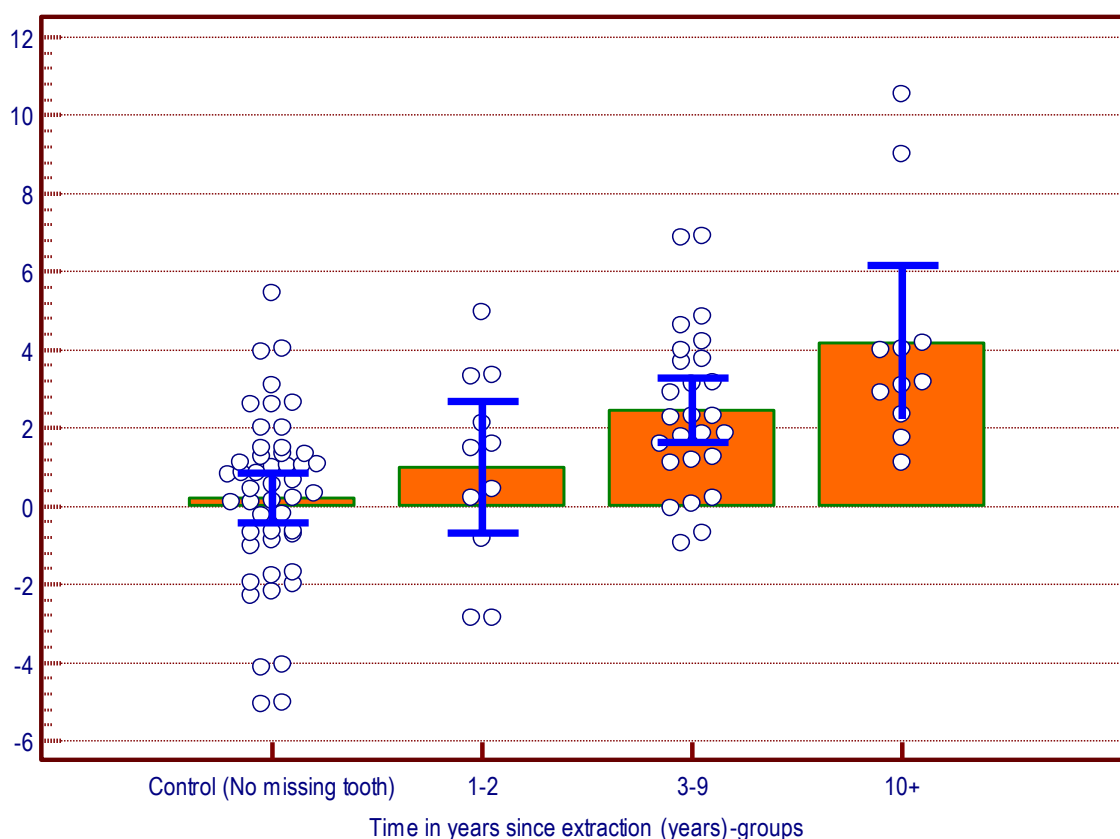


Figure 3. Dot diagram with error bars showing the mean (with its 95% confidence interval) supero-inferior differences of the sinus floor position between the side of the missing teeth and the contralateral side (mm) by time since extraction.

Table 3. Multiple linear regression models with the supero-inferior differences of the sinus floor position between the side of the missing teeth and the contralateral side (mm) as the dependent (response) variable and time since extraction in addition to age as the explanatory variables.

	Unstandardized Coefficients	P	Standardized Coefficients
(Constant)	0.383	0.56[NS]	
Age (years)	0.006	0.73[NS]	0.033
Time in years since extraction	0.230	<0.001	0.437

$R^2=0.2$ P (Model) <0.001

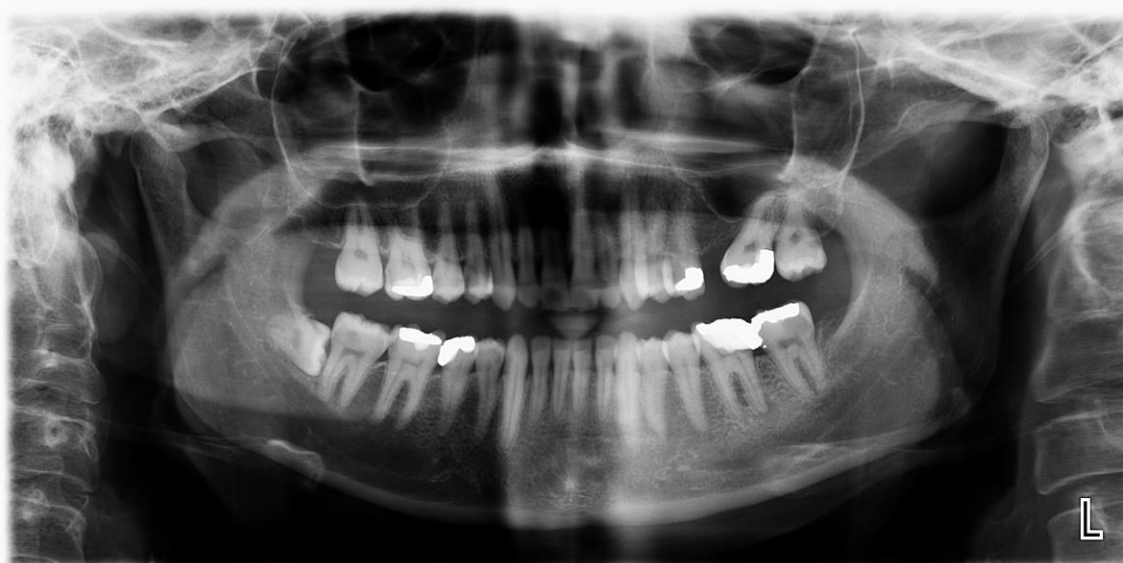

Figure 4. Left maxillary sinus pneumatization after 7 years of left maxillary first molar tooth extraction.

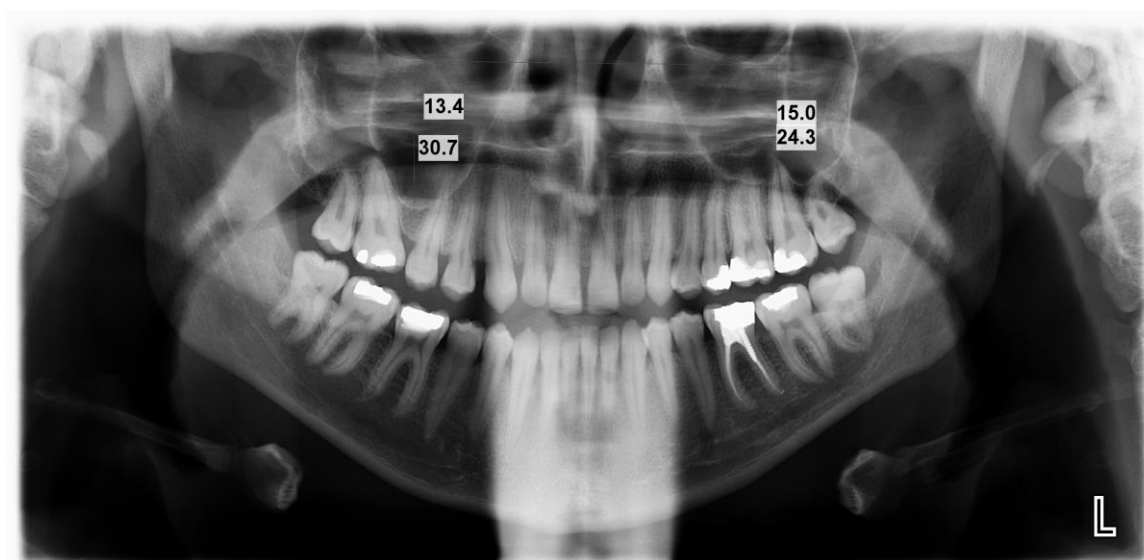


Figure 5. right maxillary sinus pneumatization after 11 years of right first maxillary molar tooth extraction.

We compare in this study between the inter-patient supero-inferior differences of the sinus floor position between the side of the missing teeth and the contralateral dentate side in experimental subject who have missing one of the closest teeth to sinus (to exclude the synergic effect of multiple missing teeth) and make with the same way a comparison with control subjects who have a predetermined side of missing tooth even he don't have a missing tooth.

A non-significant mean difference was observed in the inferior level of the maxillary sinus between the two dentate side in the control subjects and that mean difference become significant after one year of posterior tooth extraction (from 0.22 to 1) in experimental subjects, and it increase to become 2.47 after 3-9 years and jump to 4.19 after ten years and more of extraction in an average of 0.23 mm per year.

Pneumatization (which is a consequence of intrasinus positive pressure ^(27, 33, and 34)

occurs after removal of one or more of maxillary posterior teeth may extend into the residual alveolar process³⁵. This problem is especially magnified in the posterior maxilla where it combined with progressive ridge resorption in an apical direction. Based on the Cawood and Howell classification of bone loss, the residual bone crest may be classified in gradations of I (dentate) to VI (paper thin)⁽³⁶⁾. The resulting situation may affect the ability to place implants of adequate size and length⁽³⁷⁾, although minimal complications have been reported following maxillary sinus perforation during orthodontic screw placement⁽³⁸⁾, it is wise to avoid this area in patients with marked pneumatization⁽³⁹⁾.

In the present study the pneumatization of maxillary sinus after posterior tooth extraction behave in the same manner in the different age group even there is a Continuous pneumatization of the maxillary sinus (in dentate subjects), as the age of the patient progresses, in the posterior maxilla⁽³⁵⁾.

Conclusion

Pneumatization is an expected consequence after extraction of even one posterior tooth in a rate of 0.23 mm per year, and that pneumatization start in any age with the same rate.

Accordingly, decision-making challenge vastly depending on valid clinical evidence to assess the most favorable treatment modalities, maxillary sinus floor elevation procedure is nowadays the most frequently used bone augmentation technique prior to implant placement, in more of half of the cases.⁽³⁷⁾

References

1. Shea JJ. Morphologic characteristics of the sinuses. *Arch Otolaryngol.* 1936; 23:484-487.
2. Thomas A, Raman R.A. Comparative study of the pneumatization of the mastoid air cells and the frontal and maxillary sinuses. *Am J Neuroradiol.* 1989; 10(5 suppl); S88.
3. White Stuart C. & Pharoah Michael J. *Oral radiology principle and interpretation*, 6th edition, Mosby Elsevier, (2009) pp.: 521-523.
4. Ramzi T. Younis. *Pediatric sinusitis and sinus surgery.* Taylor and Francis group 2006; 32.
5. Moss-Salentijn L: *Anatomy and embryology.* In Blitzer A, Lawson W, Friedman WH, editors: *Surgery of the paranasal sinuses*, Philadelphia, PA, 1991, WB Saunders.
6. James R. Hupp, Edward Ellis III & Myron R. Tucker. *Contemporary Oral and Maxillofacial surgery.* 6th edition, Mosby Elsevier, 2014 pp.: 382-393.
7. Eberhardt JA, Torabinejad M, Christiansen EL: A computed tomographic study of the distances between the maxillary sinus floor and the apices of the maxillary posterior teeth. *Oral Surg. Oral Med Oral Pathol. Oral Radiol. Endod.* 1992; 73:345.
8. Harorh A, Bacutoglu O: The comparison of vertical height and width of maxillary sinus by means of Waters' view radiograms taken from dentate and edentulous cases. *Ann Dent.* 1995; 54:47.
9. Nowak R, Mehlis G. Studies on the state of pneumatization of the sinus maxillaries [in German]. *Anat. Anz.* 1975; 138:143-151.
10. Shapiro R, Schorr S. A consideration of the systemic factors that influence frontal sinus pneumatization. *Invest Radiol.* 1980; 15:193-202.
11. Drettner B. Measurement of the resistance of the maxillary ostium. *Acta Otolaryngol* 1965; 60:499-505.
12. Ikeda A, Ikeda M, Komatsuzaki A. A CT study of the course of growth of the maxillary sinus; Normal subjects and subjects with chronic sinusitis. *J Otorhinolaryngol Relat Spec* 1998; 60:147-152.
13. Misch CE. *Contemporary Implant Dentistry*, 3rd ed. St Louis: Mosby, 2008.
14. Wehrbein H, Diedrich P. Progressive pneumatization of the basal maxillary sinus after extraction and space closure [in German]. *Fortschr Kieferorthop* 1992; 53:77-83.
15. Weinmann JP, Sicher H. *Bone and Bones. Fundamentals of Bone Biology*, 2nd St Luis: Mosby, 1955:123-126.
16. Wehrbein H, Diedrich P. The initial morphological state in the basally pneumatized maxillary sinus—A radiological-histological study in man [in German]. *Fortschr Kieferorthop* 1992; 53:254-262.
17. Tallgren A: The reduction in face height of edentulous and partially edentulous subjects during long-term denture wears: a longitudinal roentgenographic cephalometric study. *Acta Odontol Scand.* 1966; 24:195-239.
18. Zarb GA, Bolender CL, Carlsson GE. *Boucher's Prosthodontic Treatment for Edentulous Patients*, 11ed st Louis: Mosby, 1997.
19. Packota GV, Hoover JN, Neufeld BD. A study of the height of intact alveolar bone on panoramic radiographs of adult patients. *J Prosthet Dent* 1988; 60:504-509.
20. Xie Q, Wolf J, Ainamo A. Quantitative assessment of vertical heights of maxillary and mandibular bones in panoramic radiographs of elderly dentate and edentulous subjects. *Acta Odontol Scand* 1997; 55:155-161.
21. Arbel S and David M. Maxillary sinus Pneumatization following extraction: A

- radiographic study. *Int J Oral Maxillofac Implants* 2008; 23:48-56.
22. Cenk Kilic, Kivanc Kamburoglu, Selcen Pehlivan Yuksel, Tuncer Ozen. An assessment of the relationship between the maxillary sinus floor and the maxillary posterior teeth root tips using dental cone beam computerized tomography. *Eur J Dent*. 2010 Oct; 4: 462–467
 23. James A. Eberhardt, Mahmoud Torabinejad, Edwin L. Christiansen. A computed tomographic study of the distances between the maxillary sinus floor and the apices of the maxillary posterior teeth. *Oral Surgery, Oral Medicine, Oral Pathology*.1992 March; 73:345-347.
 24. H.H Kwak, H.D Park, H.R Yoon, M.K Kang, K.S Koh and H.J Kim. Topographic anatomy of the inferior wall of the maxillary sinus in Koreans. *Inter J of Oral and Maxillofacial Surgery*. June 2004; 33: 382–388.
 25. Q Xie, K Soikkonen, J Wolf, K Mattila, M Gong, and an Ainamo. Effect of head positioning in panoramic radiography on vertical measurements: an in vitro study. *Dentomaxillofac. Radiol*.1996; 25:61-66. Published Online: January 28, 2014
 26. Ogle OE, Weinstock RJ, and Friedman E. Surgical anatomy of the nasal cavity and paranasal sinuses. *Oral Maxillofac. Surg Clin North Am*. 2012; 24:155–166
 27. Garg AK. Augmentation grafting of the maxillary sinus for placement of dental implants anatomy, physiology, and procedures. *Implant Dent*. 1999;8:36–46
 28. Smiler DG, Johnson PW, Lozada JL, Misch C, Rosenlicht JL, Tatum OH, Wagner JR . Sinus lift grafts and endosseous implants. Treatment of the atrophic posterior maxilla. *Dent Clin North Am*. 1992;36:151–186; discussion 187–188
 29. Ohba T, Langlais RP, Morimoto Y, Tanaka T, Hashimoto K. Maxillary sinus floor in edentulous and dentate patients. *Indian J Dent Res* 2001; 12:121–125.
 30. Wehrbein H, Diedrich P. Progressive pneumatization of the basal maxillary sinus after extraction and space closure [in German]. *Fortschr Kieferorthop* 1992; 53:77-83.
 31. Mercier P, Lafontant R: Residual alveolar ridge atrophy: Classification and influence of facial morphology. *J Prosthet Dent*. 1979; 41:90–100.
 32. James R. Hupp, Myron R. Tucker and Edward Ellis III. *Contemporary oral and maxillofacial surgery*.6th edits. Elsevier, 2014, p: 208-210.
 33. Smiler DG, Johnson PW, Lozada JL, Misch C, Rosenlicht JL, Tatum OH, Wagner JR Sinus lift grafts and endosseous implants. Treatment of the atrophic posterior maxilla. *Dent Clin North Am*. 1992; 36:151–186; discussion 187–188.
 34. Ronald Younes, Nabih Nader and Georges Khoury. *Sinus Grafting Techniques a Step-by-Step Guide*. Springer, 2015 p: 11.
 35. Neelima Anil Malik. *Textbook of Oral and Maxillofacial Surgery*. 3rd Edi, Jaypee Brothers Medical Publishers, 2012.
 36. Cawood JI, Howell RA. A classification of the edentulous jaws. *Int J Oral Maxillofac Surg*. 1988; 17:232–236.
 37. Seong W-J, Barczak M, Jung J, Basu S, Olin PS, Conrad HJ Prevalence of sinus augmentation associated with maxillary posterior implants. *J Oral Implantol*.2013; 39:680–688.
 38. Costa A, Raffainl M, Melsen B. Miniscrews as orthodontic anchorage: a preliminary report. *International Journal of Adult Orthodontics and Orthognathic Surgery*. 1998; 13:201–209.
 39. Cheol-Ho Paik, In-Kwon Park, Youngjoo Woo and Tae-Woo Kim. *Orthodontic Miniscrew Implants clinical applications*. Mosby Elsevier, 2009 p: 36.