

Multiple primaries of head and neck: Adeno cystic carcinoma of the larynx with follicular carcinoma of the thyroid gland Case Report

Received: 20/5/2012

Accepted: 16/7/2013

Arsalan A. M. Shem *

Salah A. Ali **

Lana Sh. Dabbagh *

Abstract

Adeno cystic carcinoma of the larynx is very rare and concomitantly with the follicular thyroid carcinoma is not reported in the literature. This case was presented to our centre because of the stridor and small anterior neck mass. Evaluation of the case showed a subglottic mass with an enhanced right thyroid mass on the CT scan. The treatment was thyroidectomy followed by total laryngectomy and bilateral neck dissection. The histopathological study of the subglottic mass showed adeno cystic carcinoma and of the thyroid mass was follicular carcinoma. The adeno cystic carcinoma of the larynx is usually asymptomatic and it has the opportunity to invade deeply before the diagnosis. Proper evaluation of the head and neck is mandatory in any laryngeal lesion.

Keywords: Adeno cystic carcinoma, larynx, follicular carcinoma

Introduction

Adeno cystic carcinoma of the larynx is very rare; the subglottis in contrast with other laryngeal malignancies is the commonest site. Women and men are equally affected by adeno cystic carcinoma^{1,2}. Some report a slight female predisposition, and their peak incidence is in the fifth and sixth decades of life³. Adeno cystic carcinomas account for less than 1% of all malignant tumors in the larynx, only about 120 cases have been reported in the literature until now⁴. Follicular thyroid carcinoma histopathologically is a differentiated tumor and is the second most common cancer of the thyroid after papillary carcinoma. The incidence of follicular carcinoma is high in areas of endemic goiter possibly due to thyroid stimulating hormone stimulation⁵. The occurrence of occult synchronous thyroid tumors in patients with laryngeal tumors has previously been reported⁶. There are reported cases of synchronous thyroid lesions with squamous cell carcinoma of the larynx⁷. The aim of reporting this case is that it is unusual and to our knowledge there has been no reported case of adeno cystic carcinoma of the larynx with follicular thyroid carcinoma.

Case Presentation:

A 55 year old female presented to our otolaryngology clinic at Rizgari Teaching Hospital, Erbil, Iraq with symptoms of dyspnea and stridor on March 2006. The patient decided to seek medical treatment outside Iraq. A CT scan of the neck demonstrated a subglottic mass and a right thyroid mass, Figure 1. She underwent total thyroidectomy on May 2006, abroad, Figure 2 a. The subglottic mass was not addressed at that stage. She received postoperative radioactive iodine treatment according to the histopathological result from the specimen of the thyroidectomy.

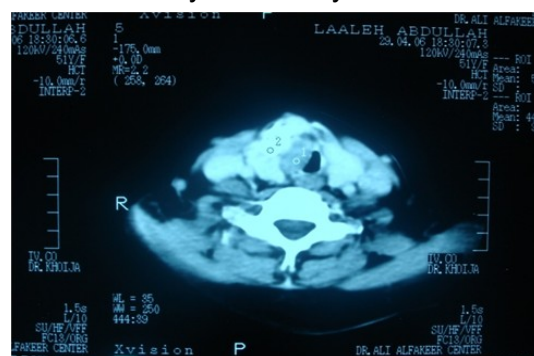

Figure 1: CT scan at April 2006 showing laryngeal and thyroid lesions (before thyroidectomy)

* Department of general surgery, College of Medicine, Hawler Medical University, Erbil, Iraq.

** Department of Pathology, College of Medicine, Hawler Medical University, Erbil, Iraq.

Total laryngectomy with bilateral selective neck dissection was performed on the patient, (levels IV, V&VI), because during the operation there was remnant of thyroid tissue. Histopathology showed negative margins around the primary (subglottic) tumor, Figure 4 a.

The specimens after total laryngectomy and neck dissection were sent for histopathological examination which revealed evidence of adenocystic carcinoma. The specimen of left neck dissection showed follicular carcinoma with glandular differentiation while the specimen from right neck dissection showed metastatic follicular carcinoma of thyroid origin, Figure 5.

There were no postoperative complications. The patient stayed 10 days at hospital. The course was uneventful and the patient was discharged on 10th postoperative day tolerating oral diet. She didn't receive further radiotherapy. The patient is currently alive with no evidence of any disease and was seen on follow up consultation. The postoperative protocol was as follows:

Monthly evaluated in otolaryngology department for the first six months & then every six month for two years, after that every year for five years. Later she will be evaluated every five years forever.

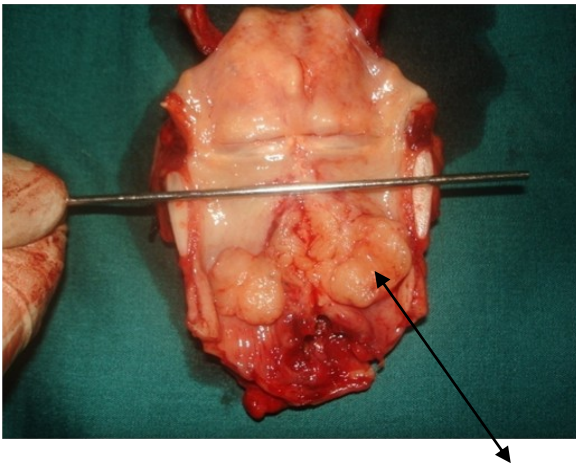


Figure 4 a: Specimen of the larynx(subglottic mass)

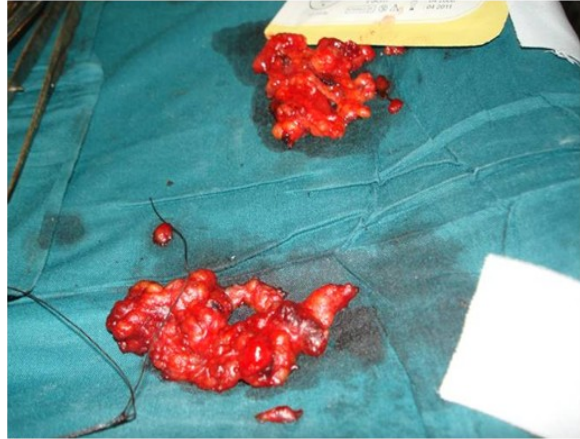

Figure 4 b: bilateral neck dissection

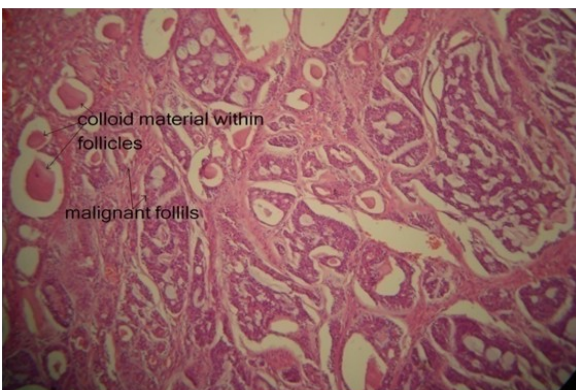


Figure 5: Follicular carcinoma of thyroid origin H&E X400

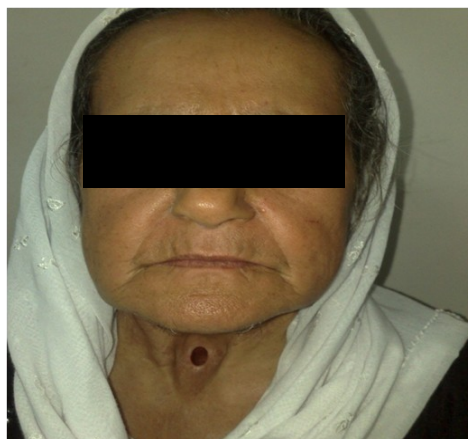

Figure 6: the patient after three years of her treatment

Discussion

Adeno cystic carcinoma usually occurs as a largely asymptomatic, nonulcerated submucosal mass. As a result, diagnosis is often delayed and, in the larynx, subglottic tumors have the opportunity to invade deeply before they are diagnosed. Preoperative histopathological analysis is essential because the symptoms do not differ greatly from squamous cell carcinoma. Subglottic tumors typically present with shortness of breath, dyspnea on exertion, and may be accompanied by hoarseness. Patient may present with a neck mass. In majority of patients symptoms were present for more than six months. On endoscopy, patients typically have a submucosal mass with normal overlying respiratory epithelium. Similarly, our patient presented with persistence hoarseness and decrease effort tolerance. The histopathological pattern of adenoid cystic carcinoma is classified into three distinct subtypes: cribriform, which is the most common; tubular, which has the best prognosis; and solid, which carries the worst prognosis⁹. Local recurrences and distant metastases (especially to the lung) are common and sometimes arise years after the primary tumor has been diagnosed and treated. Another very important factor with adenocystic carcinoma is the tendency for perineural invasion. Therefore, these patients require long-term follow-up (more than 5 years)¹⁰. Most authors agree that the treatment of choice is wide-margin local excision, partial or total laryngectomy, depending on the location and size of the tumor^{4,11,12,13}. In the absence of neck metastasis, elective neck dissection is unnecessary. Radical neck dissection is indicated for patients who have clinically or histopathologically confirmed nodal metastases. The role of radiotherapy is still open to debate. These tumors have been shown to be radiosensitive but usually not radiocurable. Therefore, radiotherapy alone usually has little role in treatment^{4,9}.

Conclusion

This is an unusual and very rare case of adenocystic carcinoma with follicular carcinoma of the thyroid gland, which has not been reported previously. Proper preoperative evaluation of the head and neck especially the thyroid is mandatory in every case of carcinoma of the larynx.

References

1. Martin AB, Laysan P. Scott-Browns Otolaryngology, Head and neck surgery. 7th ed. London: Hodder Arnold.; 2008. P. 2604.
2. Adriane PC. Malignant laryngeal lesions. Current diagnosis and treatment in otolaryngology-head and neck surgery. 2nd ed. USA: McGraw Hill LANGE; 2004. P. 463.
3. Tincani AJ, Del Negro A, Araújo PP. Management of salivary gland adenoid cystic carcinoma: institutional experience of a case series. Sao Paulo Med J 2006; 124(1):26-30.
4. Javadi M, Bafrouee FM, Mohseni M, Asghari A. Laryngeal adenoid cystic carcinoma in a child: a case report. Ear Nose Throat J 2002; 81(1):34-5.
5. Bernard H. Baily and Loves Short Practice of Surgery 24th ed. London: Hoddler headline group; 2006. P. 805.
6. Pitman KT, Johnson J, Myers E. Papillary thyroid carcinoma associated with squamous cell carcinoma of the head and neck: significance and treatment. Am J Otolaryngol 1996; 17:190-6.
7. Farrag T, Lin F, Cummings CH, Sciubba JJ, Koch WM, Flint PW, Tufano RP. Importance of routine evaluation of the thyroid gland prior to open partial laryngectomy. Arch Otolaryngol Head Neck Surg 2006; 132:1047-51.
8. Moran CA, Suster S, Koss MN. Primary adenoid cystic carcinoma of the larynx and lung. A clinicopathologic and immunohistochemical study of 16 cases. Cancer 1994; 73:1390-7.
9. Cotton RT, Seid AB. Management of extubation problem in the premature child: anterior cricoid split as an alternative to tracheotomy. Ann Otol Rhinol Laryngol 1989; 89:508.
10. Ganly I, Patel SG, Coleman M, Ghossein R, Carlson D, Shah JP. Malignant minor salivary gland tumors of the larynx. Arch Otolaryngol Head Neck Surg 2006; 132:767-70.
11. Dexamble P, Huth J, Rebufy M, Chabrol A. Cystic adenoid carcinoma of the larynx: two cases. Ann Otolaryngol Chir Cervicofac 2003; 120(4):244-8.
12. Kufeld M, Junker K, Sudhoff H, Dazer S. Collision tumor of a hypopharyngealadenoidcystic carcinoma and a laryngeal squamous cell carcinoma. Laryngorhinootologie 2004; 83(1):51-4.
13. Olofsson J, van Nostrand AW. Adenoid cystic carcinoma of the larynx: a report of four cases and a review of the literature. Cancer 1977; 40(3):1307-13.