

NEUROENDOSCOPY EXPERIENCE IN BASRAH

Khalid N Mayah

Neurosurgeon, MB.ChB, F.I.C.M.S, College of Medicine, Basrah, Iraq. www.k-neurosurg.com

Abstract

In the last decade the endoscope became one of the most important neurosurgical tools, its use increasing with time and gaining popularity.

Since May 2005, forty six neuroendoscopy procedures were performed in two hospitals in Basrah, 34 were Endoscopic third ventriculostomies (ETV) to treat hydrocephalus, three arachnoids cyst fenestrations, three ventricular tumor biopsies, and one operation to remove third ventricle tumor partially that already biopsied, three colloid cyst removed and one septotomy to treat encysted hydrocephalus, One case of craniopharyngioma had catheter implanted via the endoscope.

The patients' age ranged from 3 weeks to 70 years, However of the patients who had ETV, 37% (11/34) were younger than one year age.

Over one week to twenty months (mean follow up period were 11 months), During that time and for patients who had ETV symptoms of raised intracranial pressure that necessitated a shunt define the failure of treatment, That encountered in two patients , both were younger than one year age. Although time of follow up was rather short, the success rate was 100% for patients older than one year of age who had definite obstructive hydrocephalus.

ETV has become the treatment of choice for certain pediatric and adult hydrocephalic conditions. Saving patients from shunt dependence and complications improving the outcomes and avoiding subsequent morbidity and mortality.

Introduction

Neuroendoscopy started early in the twentieth century, But endoscopy didn't role in neurosurgery as wide as it did in other specialities, mainly because of the need for more sophisticated instruments, which was available only in the last couple decades.

The Neuroendoscope's role became essential for the management of many neurosurgical cases and the use of extracranial shunt became an old treatment for hydrocephalus with its many complications. By using the endoscope, management of many untreatable intraventricular lesions became a routine neurosurgical procedure.

Third ventriculostomy adopted to replace the traditional treatment by V-P

shunt for many cases in our practice and up to date (Feb 2007) 34 patients were treated, Further twelve Endoscopic procedures were performed for different intraventricular pathologies.

This article reviews those cases, the indications, procedures performed, their outcome and complications encountered.

Endoscopic Third Ventriculostomy:

Ventriculostomy was one of the oldest treatments for hydrocephalus¹; Dandy was the first who described this procedure in 1922, but the first successful procedure were performed by William Mixter by using a urethroscope in 1923². At that time the endoscope used had poor magnification and illumination which made neuro-

endoscopy difficult and unreliable. In 1952, the shunt was introduced as a simple and reliable treatment for hydrocephalus, which ends the early era of the neuroendoscopy. The advances in endoscope technologies and the high rate of shunt failure and complications promoted neurosurgeons to review this old treatment for hydrocephalus (ETV). After 1990, many series were published with variable success rates for ETV that ranged from 55-90%³.

The rationale for Endoscope Third Ventriculostomy:

The real advantage of ETV is elimination of the reliance on mechanical shunts with all their limitations (40% of patients required a shunt revision within 2 years of initial shunt placement)⁴, It returns CSF dynamics to essentially normal status in patients with obstructive hydrocephalus, with better long term success rate.

There are no low pressure complications as seen with VP shunt and being a short procedure, patient anesthesia and

operation time is significantly reduced. Hospital stay is short and overall the procedure is much more economical than a VP shunt. It also avoids infection⁵. There is no abdominal incision and it can be done by local anesthesia in cooperative patients⁶.

Method

Forty-six consecutive Neuroendoscopy procedures were performed for 45 patients over 21 months (from May 2005 to Feb.2007) in two hospitals, (Basrah Teaching Hospital 15/46), and (AL Moosawi Private Hospital 31/46). This is a prospective study, all the patients were recorded in electronic data base that includes their clinical records; follow up visits, radiological investigations and in most of them a video of the procedure.

The endoscope most commonly was used to manage hydrocephalus (35/46), (ETV) were the procedure performed for all of them except one septotomy to treat unilateral hydrocephalus for shunted female(Fig.1).

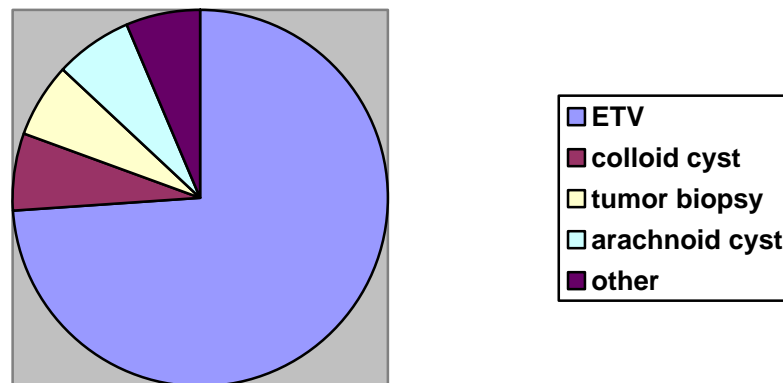


Fig.1: distribution of the cases operated by endoscope, ETV was the commonest procedure.

Clinical material (ETV):

Thirty-four patients were submitted for ETV over 21 months between May 2005 and Feb. 2007. Their ages ranged from 2 weeks to 70 years (mean age = 15.6 years).

As many authors believe that ETV outcome is different among those who are younger than one year of age than older ones (3-5,7-10), we divided the

patients to two groups, Eleven patients (37%) were younger than one year of age, and 23 (63%) were older, All had definite clinical features of raised intracranial pressure. CT scan, MRI or both were done for all of them and showed the definite signs of hydrocephalus, the lateral and third ventricles dilatation with small fourth ventricle were a sign of obstruction (table I).

Type of hydrocephalus or pathology related	Number of cases	%
Posterior fossa tumor	9	26.1%
Myelomeningocele associated	8	23.5%
Congenital aqueduct stenosis	5	14.7%
Shunt Malfunction	5	14.7%
Posterior third ventricle mass (arachnoids cyst and aneurismal vein of Galen)	2	5.8%
Dandy Walker syndrome	2	5.8%
Acquired aqueduct stenosis	2	5.8%
Normal pressure hydrocephalus	1	2.9%
Total	34	

Table I: The type of hydrocephalus or the pathology related.

A patient was considered a candidate for the procedure, when he/she had definite symptoms of raised intracranial pressure and radiological finding suggesting obstructive nature of the hydrocephalus.

Hospital stay ranged from 2-9 days with a mean of 3.2 days. Most of the patients admitted in the same day of the procedure and discharged 48 hours after, unless there was a complication that required more inpatient follow up.

The follow up period was ranged from one week to 20 months (mean were 11 months). The failure of treatment was defined by the need for a shunt. The

symptoms relieve and head circumference increment in patients younger than one year of age was an indicator during the follow up period.

The procedure (ETV):

Under General anesthesia a right precoronal parasagittal Burr hole were done , the trochar with stylet inserted into the lateral ventricle, the endoscope inserted and navigated to the foramina Monroe, When the landmarks were identified (two mamillary bodies and area vasculosum) the site of the supposed

stoma was planned at mid-way between mamillary bodies and infundibular recess in the midline. The stoma was mostly performed and dilated by fogarty catheter Fr.2, sometime blunt biopsy scissor or diathermy probe were used to create the perforation (Fig.2). Normal

Saline irrigation was used profusely and drain was kept patent. Time consumed in the procedure was ranged from 15-50min (mean time 33 min). All patients were admitted for the ICU or observed for 24 hours after surgery.

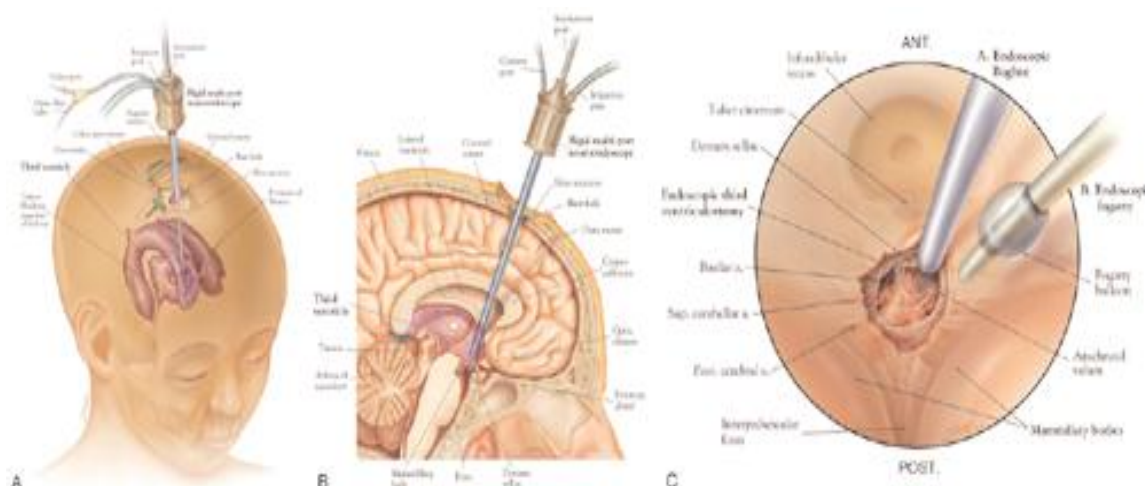


Fig.2: A- Site of the precoronal parasagittal burr hole. B-The endoscope navigated to the foramen Monro and to the floor of the third ventricle. C-The perforation of the floor and dilatation using Fogarty catheter, two mamillary bodies below.

Results (ETV):

The procedure was done successfully in all the patients except two, in whom an unfavorable anatomy were encountered in the floor of the third ventricle at which time the procedure aborted and shunt implanted. One of them had aqueduct stenosis, while the other had shunt malfunction that was complicated by ventriculitis.

In the first group (younger than one year age), 11 patients had successful procedure, 6 of them having Myelomeningocele-associated hydrocephalus, 3 with congenital aqueductal stenosis, and 2 with Dandy-Walker syndrome.

During the follow up period two patients

aged 3 and 4 months, who had congenital aqueduct stenosis experienced recurrence of the symptoms 4 and 2 months after the procedure respectively and for that shunt were needed. In this group of patients the success rate was 81% (9/11) (Table II).

In the second group (more than one year of age), 21 patients had successful procedure (21/23), 9 of them had hydrocephalus due to posterior fossa tumor, 5 due to shunt malfunction, 2 due to posterior third ventricle mass, 2 acquired aqueduct stenosis, 2 congenital aqueduct stenosis, 2 were myelomeningocele-associated and one patient has normal pressure hydrocephalus.

Age group	Number of cases	Successful procedure	Out come (Shunt free)
Group NO. 1 younger than one year age	11	11/11	9/11 81%
Group NO.2 Older than one year age	23	21/23	17/17 100%
Total	34	32/34	26/28 92.8%

Table II: The procedures success and out come in relation to the age.

One patient who had myelomeningocele-associated hydrocephalus died one week after discharge from the hospital due to chest infection. Three patients were lost for follow up, two of them had serious pathology (aneurismal vein of Galen and

posterior fossa tumor), the other 17 patients were free of shunt during the follow up period and the overall success rate is considered to be 100% for them (Tab II).

Type of hydrocephalus	Number of cases	Procedure success	Outcome (Shunt free)	complication
Posterior fossa tumor	9	9/9	8/8	3/8 CSF leak
Myelomeningocele associated	8	8/8	6/6	1/6CSF leak 1/6 fit
Shunt malfunctions	5	4/5	4/4	1/4 CSF leak
Congenital aqueduct stenosis	5	4/5	2/4	2/4 fit
Acquired aqueduct stenosis	2	2/2	2/2	0/2
Posterior third ventricle mass	2	2/2	1/1	0/1
Dandy Walker Syndrome	2	2/2	2/2	0/2
Normal Pressure hydrocephalus	1	1/1	1/1	0/1
Total	34	32/34	26/28	8/34

Table III: The procedure related complications in relation to pathology or type of hydrocephalus

Complications (ETV):

There was no mortality or major morbidity related to the procedure. Five patients developed CSF leak either from the site of burr hole or craniotomy in subsequent surgeries, 3 of them respond well to medical treatment (diuretics), and

two for single/couple lumbar punctures (Tab. III).

Three patients experienced repeated fits in the early postoperative period that responded well to antiepileptic treatment. One of them though was admitted for that in the ICU for 5 days.

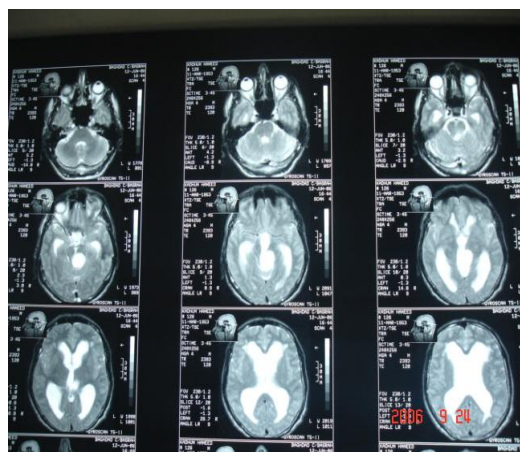


Fig. 3: MRI scan before (left) and 3 months after ETV (right), The ventricle size is smaller and there is no per ventricular oedema in the post treatment scan.

Discussion (ETV):

Since the rediscovery of the ETV in the last decades of last century, the controversies on its indications existed. Variable success rates suggested the differences in benefit according to age/type of hydrocephalus or the pathology related.

In this series we considered a patient as candidate for ETV when the CT scan or MRI of the brain showed dilated lateral and third ventricles with small or invisible fourth ventricle, or if there was obstructive pathology. The age was not considered as a contraindication for the procedure.

Recent reports support the evidence that the ETV outcome is more related to the cause than the age^{7,11,15}, Mehdorn HM et al, In their experience with ETV in infant gave a 10% success rate in communicating hydrocephalus, 100% success in obstructive ones and 50% in meningocele-associated hydrocephalus.

Then concluded that the outcome was related to the cause of hydrocephalus⁷. Although there is some controversy about this age group, some endoscopist still report low success rate in patients of less than 2 years of age yet, they didn't consider the age a contraindication for the procedure^{10,15,19}.

Many endoscopists report one or two failures to perform the stoma in their series, and some even reported 31% failure rate (15). In two patients the procedure was aborted and a shunt implanted at the same time. That finding further stresses the importance of the learning curve in Neuroendoscopy that is already recognized^{3, 10, 20-22}.

The success rate of ETV in the first group (infants) is 81% (9/11) which is higher than many other reports, but the follow up time still is shorter than most of them^{7, 12, 15, 18, 19}. Etuis V, et al, reported in analysis of the results in subgroups with different etiologies of

hydrocephalus in infants, that the success rate of the procedure was 83% in patients with defined anatomic obstruction¹⁹.

Khan W. Li, et al, reported 89% success rate in patients who had hydrocephalus due to tectal glioma²³.

The success rate of ETV in infants in most of the series ranged from 56% to 89%, although the success rate is higher in selected subgroup¹⁹⁻²². This may reflect the necessity of patients' selection for this treatment. Anyhow the advantage of having more shunted free patients in this age group should not be denied and the decision should consider each patient with his type of hydrocephalus. Shunt failure unfortunately is encountered more in this age group. The decision to select between those two treatments modalities should consider the treatment risks, results for the same subgroup of the patient, and complications. All have to be discussed with the family. The result of 70% failure rate of the shunt over ten years, should be compared with 75 % overall success rate in endoscopic treatment, yet there is no way of predicting which patient will benefit from the procedure²⁴.

In this series the success rate in patients older than one year age was 100% (17/17), in many larger series this result has been reported^{14,16}. Singh D, et al, reported in their series a 100% success rate in 17 adults and children older than two years¹⁴, although in a series where the follow up period was longer and included different etiologies for raised ICP the success rate was less and ranged from 60-95%^{3-5,9,11,14,17}.

Few articles discussed the benefits of ETV in patients of myelomeningocele-associated hydrocephalus and their results were variable (50-71%)²⁴, those cases represented a large part of our case load (8/34). The six patients who were followed up are still shunt-free. Many authors studied the benefit of ETV in

patients who have malfunctioning shunt and most concluded that it had high success rate^{3,5,14,24}. ETV has been reported to have a 76.7 to 77% success rate in those patients²⁵⁻²⁷. In this series all four patients who presented with shunt malfunction had symptomatic relief after ETV, two of them regained consciousness one day after the procedure and the result is highly encouraging of adopting ETV rather than shunt-revision for patients who presented with shunt malfunction.

All eight patients who had posterior fossa tumor and hydrocephalus continued to be shunt-free before and after their surgery for tumor removal. Many articles reported high success rate in this group²⁸⁻³⁶. Morelli D, et al, reported 81% success rate in his management for 22 patients³⁴.

It is well known that the radiological improvements after ETV are less than that following shunt. As the liquor is maintained in the same physiological space, the ventricle will not shrink as in patients who have functioning shunts. Nowoslawska E, et al, studied the ventricle size and head enlargement after ETV and compared the finding with patients who had shunts and concluded that patients treated with ETV had larger ventricle and head circumference and that it was not related to their clinical improvement¹⁶, a belief shared by many other authors^{3,5,8,16}.

In this series, post treatment scan were done for 14 of 34 patients and were preserved until clinical suspicion of malfunction stoma encountered in others, in those 14 cases the ventricle size were smaller than before treatment and there were no periventricular oedema. Unfortunately cine phase contrast (MRI) study that can define CSF flow in the stoma is not available in our radiological centers yet; it can be useful even to define aqueduct stenosis³⁶. Many authors investigate their patients by CT scan or MRI, and depend

on the rule of dilated lateral and third ventricles and small fourth one to define the obstructive nature of hydrocephalus^{4,5, 7}.

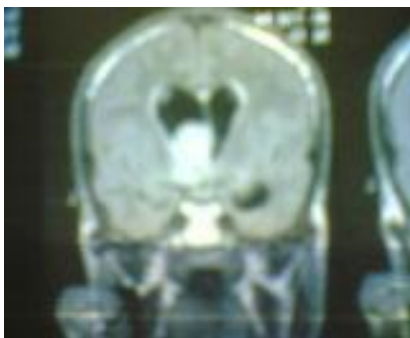
The incidence of complications with ETV has been reported in many large series ranging from 0 to 43%^{3,4,9,23-31}, the overall rate of complications encountered is 23%. No patient suffered permanent disability or morbidity and no procedure-related mortality were reported. The complications included three patients who had fit after the procedure, that were responded well to antiepileptic treatments and another five patients who had CSF leak that were complicate their surgery for removing

the posterior fossa tumors or from the site of burr hole itself, however three of them respond to diuretics treatment and two to L3-4 lumbar punctures. There is no report of similar complications in many series that discussed ETV complications, although literatures on ETV describes various procedure – related complications that we did not report in our series, such complications include, basilar artery injury⁸, endocrinopathy caused by hypothalamic or pituitary stalk injury, which typically manifests as diabetes insipidus³, cardiac arrhythmia^{12,23,32}, postoperative infections^{37,38}, subdural haematoma and subglial abscess³⁹.

Endoscopic procedures Other than ETV:

Tumor biopsy:

Three patients had Endoscopic procedures to biopsy their intraventricular tumors, two of them were in the lateral ventricle and one was in the third ventricle. The procedures were done successfully in all of them



and the result of the histopathology was astrocytoma grade II, ependymoma and craniopharyngioma (Fig.3). All three patients had a shunt implanted at the same session. One of them was submitted for another endoscopic procedure to remove the tumor later on.

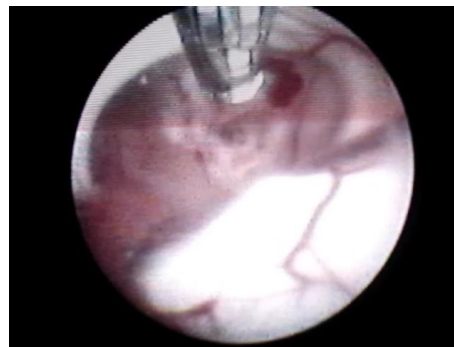

Fig.3: Third Ventricle tumor biopsy, astrocytoma grade II

Colloid Cyst:

Three patients had endoscopic surgery to remove colloid cysts. Their ages were ranged from 34-46 years, all of them had hydrocephalus and symptoms related to it. The procedure time ranged from 90-130 min. All had MRI scan postoperatively that proved total removal and relief of hydrocephalus and all were improved clinically (Fig.4), most authors reported similar results^{39,40,41}. In most of the series, 1-7 cases of colloid cysts

reported. The lesion, which is rare, is treated by different modalities. Shunt was the oldest one, and is mostly abounded, stereotactic aspiration associated with high recurrence rate^{42,43} and microscopically open surgery had high morbidity rate. Lastly the endoscopic removal proved to yield low recurrence and morbidity rates; it should be suggested as the therapy of first choice⁴².

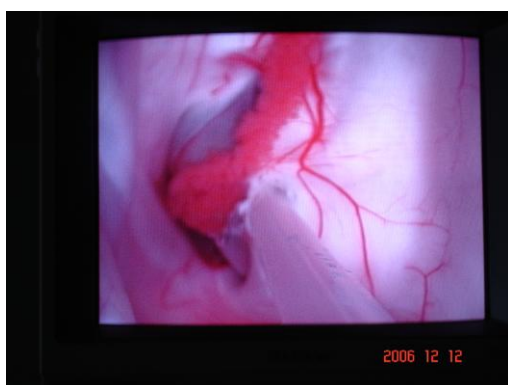
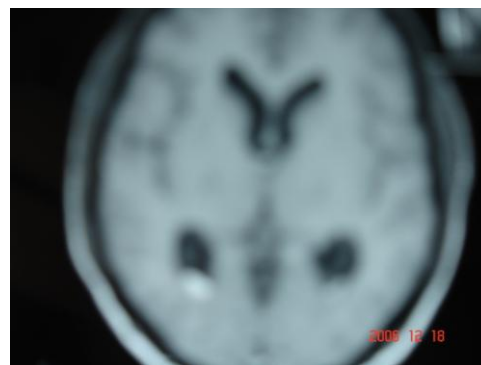
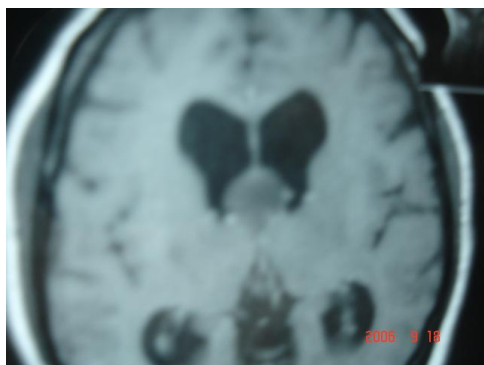


Fig.4: Colloid cyst

A- MRI before treatment the cyst in the roof of the third ventricle on roe

B- The endoscopic view shows the cyst obstructing the foramena Monroe, the catheter first used to aspirate the colloid material

C- The MRI in the third post operative day, the cyst removed totally.

Arachnoid cyst:

One patient of 12 years old and two infants were operated on to fenestrate an intraventricular arachnoid cyst. The procedure was done successfully in all of them, two were well in the follow-up period, while one infant who had a shunt implanted in the same session developed severe dyspnoea and abdominal distension, which may be explained by shunt overdrainage and died two days post operatively. The overall success rate of endoscopically treated arachnoid cysts in a larger series was 70%³⁷. Neuroendoscopy is a safe and effective treatment option for arachnoid cysts and should be seriously considered as the initial therapy⁴¹.

Others: One patient was operated on to remove his third ventricle ependymoma

and had partial removal. There was no morbidity related to surgery and discharged 4 days after the procedure.(Fig.5)

A patient who had craniopharyngioma occupying the third ventricle had catheter placement through the endoscope and a reservoir implanted to aspirate the fluid. She had CSF leak that respond to diuretic treatments. The cyst get smaller and submitted to radio surgery treatment (Fig.6).

Another patient with craniopharyngioma who had a right side shunt done two years ago presented with headache her MRI scan shows dilated left ventricle and the craniopharyngioma obstructing the foramen Monroe. Septotomy was done for her and she was saved another shunt (Fig.7).

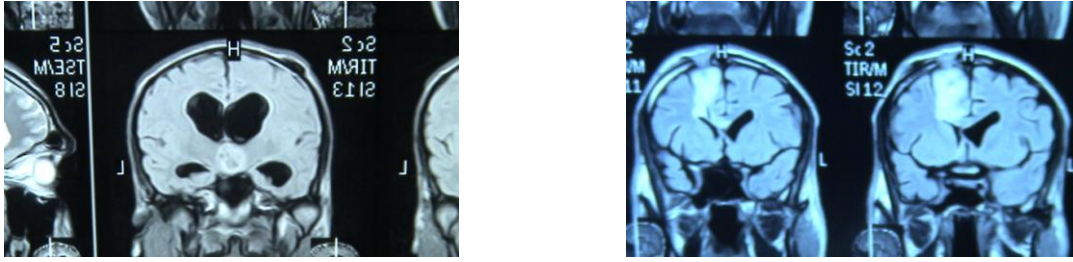


Fig.5: MRI before (left) and after (right) partial removal of third ventricle ependymoma.



Fig.6: CT scan shows Craniopharyngioma (left), it was obstructing the foramina Monroe, (right) catheter implanted via endoscope to the cyst.

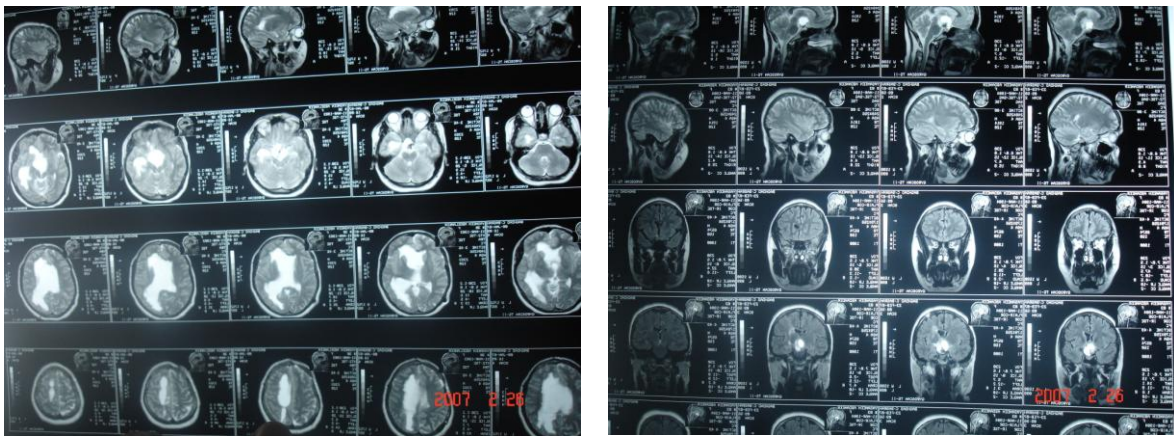


Fig.7: MRI shows unilateral dilated ventricle in shunted female (left), after septotomy (right) MRI shows normal size ventricles.

Conclusion

ETV is a logical alternative to the external divertional procedure (V-P shunt). The result is better in patients with more than one year of age who have definite obstruction. It can be useful in patients who have myelomeningocele-associated hydrocephalus. Patients who have shunt

malfunction can be a candidate for the procedure to be shunting independent. Fits are expected in the early post operative period, so all patients should have post operative monitoring and the need for prophylactic antiepileptic should be investigated.

Neuroendoscope is ideal to treat colloid cysts, arachnoid cysts and to biopsy

intraventricular tumors. We believe that, as a result of its low morbidity the indications for endoscopy will continue to be extended.

I acknowledge the efforts of Prof. Safwan A. Taha, CABS for his great support in writing this article. Prof. Vance O. Gardner, M.D., Orthopedic

Specialty Institute executive director, Michael G Muhonen, M.D. Pediatric Neurological Surgery, Juliana Ditty (Global Operation and Giving Children hope), Mr. Raymond N. Joekel, who worked together to help me achieving the Neuroendoscopy training in California.

Reference:

- 1-George I. Jallo, M.D., Endoscopic third Ventriculostomy, *Neurosurg Focus* 19 (6):E11, 2005
- 2-Khan W. Li, M.D., et al, Neuroendoscopy: past, present, and future, *Neurosurg Focus* 19 (6):E1, 2005
- 3-Neil Buxton, F.R.C.S. (Ed), Neuroendoscopic third ventriculostomy, *Neurosurg Focus* 6 (4): Article 2, 1999
- 4- Amen Amini, M.D., M.Sc., and Richard H. Schmidt, M.D., Ph.D. Endoscopic third ventriculostomy in adult patients, *Neurosurg Focus* 19 (6):E9, 2005
- 5- George I. Jallo, M.D., Karl F. Kothbauer, M.D., and I. Rick Abbot, M.D., Endoscopic third ventriculostomy, *Neurosurg Focus* 19 (6):E11, 2005
- 6- Longatti PL, et, al, A simplified endoscopic third ventriculostomy under local anaesthesia, *Minim Invasive Neurosurg.* 2004 Apr; 47(2):90-2.
- 7-Mehdorn HM, et, al, Endoscopic third ventriculostomy in infants, *J Neurosurg.* 2005 Jul; 103(1 Supply):50-3.
- 8- Baykan, et al : Ten Years of Experience with Paediatric Neuroendoscopic Third Ventriculostomy: Features and Perioperative Complications of 210 Cases
- 9- Amin Amini, M.D., M.Sc.; Richard H. Schmidt, M.D., Ph.D., Endoscopic Third Ventriculostomy in a Series of 36 Adult Patients, *Neurosurgical Focus* 2006-09-23
- 10- Neil Buxton: Neuroendoscopic third ventriculostomy. *Neurosurg Focus* 6 (4): Article 2, 1999
- 11- Hellwig D, et, and al: Endoscopic third ventriculostomy for obstructive hydrocephalus, *Neurosurg Rev.* 2005 Jan; 28(1):1-34; discussion 35-8. Epub 2004 Nov 27.
- 12- Giuseppe Cinalli, M.D., Failure of third ventriculostomy in the treatment of aqueductal stenosis in children, *Neurosurg Focus* 6 (4): Article 3, 1999.
- 13- Rachel Fudge: Third Ventriculostomy: A promising procedure that may offer freedom from shunt dependency, Winter 1996 Newsletter.
- 14- Singh D: Endoscopic third ventriculostomy in obstructed hydrocephalus, *Neurol India* 2003;51:39
- 15 - Benjamin C. Warf, M.D., Lynda MacGowen, R.N. Endoscopic Third Ventriculostomy: Initial Experience at CURE Children's Hospital of Uganda, International Federation of spina bifida and hydrocephalus web site, www.ifglobal.org
- 16-Nowoslawska E, et, al, Influence of Neuroendoscopic third ventriculostomy on the size of ventricles in chronic hydrocephalus, PMID: 15605466 [PubMed - indexed for MEDLINE]
- 17- Feng H, et al , : Endoscopic third ventriculostomy in the management of obstructive hydrocephalus: an outcome analysis. *J Neurosurg.* 2004 Apr; 100(4):626-33
- 18- N. Buxton, et, al, Neuroendoscopic Third Ventriculostomy in Patients Less than 1 Year Old, *Pediatric Neurosurgery* 1998;29:73-76 (DOI: 10.1159/000028693).
- 19-Etus V, Ceylan S.: Success of endoscopic third ventriculostomy in children less than 2 years of age, PMID: 16041551 [PubMed - indexed for MEDLINE]
- 20- Grunert P, Perneczky A, Resch K. Endoscopic procedures through the foramen intraventriculare of Monro under stereotactic conditions. *Minim Invasive Neurosurg* 1994; 37:2-8.
- 21 Mc Laughlin MR, Wahlig JB, Kaufmann AM, Albright AL. Traumatic Basilar aneurysm after endoscopic third ventriculostomy: case report. *Neurosurgery* 1997;41:1400-4.
- 22- Cinalli G, Sainte-Rose C, Chumas P, Zerah M, et,al. Failure of Third ventriculostomy in the treatment of aqueductal stenosis in children. *J Neurosurg* 1999;90:448-54.
- 23- Khan W. Li, M.D., Endoscopic Third Ventriculostomy for Hydrocephalus Associated With Tectal Gliomas, *Neurosurgical Focus* jul.2005.

- 24-Michael Vloeberghs MD, Senior Lecturer in Pediatric Neurosurgery & Honorary Consultant Paediatric Neurosurgeon, Queens Medical Centre, University of Nottingham.; Re-inventing the Wheel or Third Ventriculostomy, international Federation of spina bifida and hydrocephalus web site, www.ifglobal.org
25. Cinalli G, Salazar C, Mallucci C, et al: The role of endoscopic third ventriculostomy in the management of shunt malfunction. *Neurosurgery* 43:1323--1329, 1998 20.
26. Mallucci CL, Vloeberghs M, Punt JA: Neuroendoscopic III ventriculostomy: the first-line treatment for blocked ventriculo-peritoneal shunts? *Childs Nerv Syst* 13:498, 1997 (Abstract)
- 27- Mc Laughlin MR, Wahlig JB, Kaufmann AM, Albright AL. Traumatic Basilar aneurysm after endoscopic third ventriculostomy: case report. *Neurosurgery* 1997; 41:1400-4.
- 28- Gangemi M, Donati P, Maiuri F, et al: Endoscopic third ventriculostomy For hydrocephalus. *Minim Invasive Neurosurg* 42:128-132, 1999
- 29- Hoffman HJ, Harwood-Nash D, Gilday DL: Percutaneous third Ventriculostomy in the management of noncommunicating hydrocephalus. *Neurosurgery* 7:313-321, 1980
- 30 -Jones RF, Kwok BC, Stening WA, et al: The current status Of endoscopic third ventriculostomy in the management of noncommunicating Hydrocephalus. *Minim Invasive Neurosurg* 37:28-36, 1994
- 31- Schroeder HW, Niendorf WR, Gaab MR: Complications of endoscopic Third ventriculostomy. *J Neurosurg* 96:1032-1040, 2002
- 32-D, et, al, Endoscopic third ventriculostomy in the treatment of hydrocephalus in posterior fossa tumours in children, *Childs Nerv Syst*. 2004 Nov; 20(11-12):828-33. Epub 2004 Jun 25. .
- 33-Ruggiero Cet,al,:Endoscopic third ventriculostomy in the treatment of hydrocephalus in posterior fossa tumors in children
- 34-Morelli D,et al, : Persistent hydrocephalus after early surgical management of posterior fossa tumors in children: is routine preoperative endoscopic third ventriculostomy justified?, *J Neurosurg*. 2005 Sep;103(3 Suppl):247-52.
- 35-Fritsch MJ,: Hydrocephalus in children with posterior fossa tumors: role of endoscopic third ventriculostomy., *J Neurosurg*. 2005 Jul;103(1 Suppl):40-2.
- 36-Mandat T,: [Neuroendoscopy in the treatment of third ventricular hydrocephalus accompanying tumors of the posterior part of the third ventricle in children] *Neurol Neurochir Pol*. 2002 Jul-Aug;36(4):711-22.
- 37-Hopf, Nikolai J. MD; Perneczky, Axel PhD,: Endoscopic Neurosurgery and Endoscope-assisted Microneurosurgery for the Treatment of Intracranial Cysts [Clinical Studies], July 21, 1998.
- 38- Kadrian, David B.Med,: Long-term Reliability of Endoscopic Third Ventriculostomy [Clinical Studies: ENDOSCOPY: HYDROCEPHALUS], February 7, 2005.
- 39- Laszlo Bognar, M.D., Ph.D.: Retrospective analysis of 400 neuroendoscopic interventions: the Hungarian experience, *Neurosurg Focus* 19 (6):E10, 2005 40- Michael R. Gaab, M.D., Ph.D., and Henry W. S. Schroeder, M.D.: Neuroendoscopic approach to intraventricular lesions, *Neurosurg Focus* 6 (4):Article 5, 1999
- 41- Henry W. S. Schroeder, M.D., and Michael R. Gaab, M.D., Ph.D.: Intracranial endoscopy , 2004 AANS.
- 42-Phillippe Decq , M.D. :Endoscopy in Neurosurgery-The DECQ Neuroendoscope.
- 43-. Mathiesen T, Grane P, Lindquist C, et al: High recurrence rate following aspiration of colloid cysts in the third ventricle. *J Neurosurg* 78:748--752, 1993